FOOT & ANKLE INTERNATIONAL

Assessment of Talar Flattening in Adult Idiopathic Clubfoot

Christian M. Bach, M.D.; Georg Goebel, M.Ph.D.; Eckart Mayr, M.D.; Rainer Biedermann, M.D.; Franz Rachbauer, M.D.
Innsbruck, Austria

ABSTRACT

Background: **The radius/length (R/L) ratio was developed to evaluate the convexity of the talar dome in idiopathic clubfoot. However, the index has not been tested for its reliability and reproducibility.** ***Methods:*** **The R/L ratio was determined by three independent observers on the radiographs of 21 adult patients with idiopathic clubfoot and 30 adult subjects with normal feet. The reproducibility and the reliability of the R/L ratio were calculated.** ***Results:*** **For the normal feet the reproducibility and the reliability of the R/L ratio was high (correlation coefficient > 0.87). For the patients with clubfoot, the reliability and reproducibility depended on the severity of talar flattening. For a radius of less than 45 mm the mean intraobserver correlation coefficient was 0.74 (range 0.54 to 0.83) and the mean interobserver correlation coefficient was 0.58 (range 0.49 to 0.75). For a radius of more than 45 mm no statistically significant intraobserver and interobserver correlations were found.** ***Conclusion:*** **The current results indicate that the R/L ratio of talar flattening is reliable and reproducible for mild talar deformity but not for severe flattening (radius of more than 45 mm).**

Key Words: Clubfoot; Flat Top Talus; Radius/Length Index; Radiographic Assessment

INTRODUCTION

The frequency of talar flattening in patients treated for idiopathic clubfoot has been inconsistent in different series.[1–4,12,14,17–19,21] Some authors did not discuss talar flattening.[7,8,16,22,24] While others reported occurrences ranging from 1.5%[14] to 100%[4] of patients. Anatomic studies have shown that deformation of the talus is common in clubfoot,[13,25,26] but the degree of talar flattening rarely was assessed in a standardized way. Some authors reported the total frequency of flat-top talus without any classification.[9,17] Others tried to approximate the surface of the dome to a semicircle.[3] Flattening of the talar dome can be graded as none, mild, moderate, or severe.[2,4,21]

The radius/length (R/L) ratio, an index of talar flattening, is a well-defined method that provides a numerical value expressing the extent of flattening.[10] It is determined by measuring the radius (R) of the trochlear curvature of the talar dome and the length (L) of the talus from its posterior extremity to the distal portion of the head. It provides a useful measurement for comparing retrospective studies, i.e. to compare the efficacy of different methods of treatment.[12] However, to the best of our knowledge, the index has not been tested for its reliability and reproducibility. A measurement system should be reproducible from one observer to the next, as well as by one observer on separate occasions. An absence of interobserver reliability does not allow a valid comparison of patients from different centers. Absence of intraobserver reproducibility compromises the results of outcome studies that were done over a period of time within the same center or by the same observer or group of observers.[29] Evaluations of orthopaedic classification systems have reported disappointing results for interobserver reliability and intraobserver reproducibility.[5,6,20,27–29,31] This study was done to determine the intrinsic error in the R/L ratio when the same observer (intraobserver reproducibility) and when different observers (interobserver reliability) measured the same radiographs. In addition, the possible sources of error were evaluated. It was hypothesized that the extent of talar flattening might influence the reliability of R/L ratio measurements.

[1]Department of Orthopaedic Surgery, University of Innsbruck, Innsbruck, Austria
[2]Department of Biostatistics, University of Innsbruck, Innsbruck, Austria

Corresponding Author:
Christian M. Bach, M.D.
Department of Orthopaedics
Innsbruck Medical University
Anichstrasse 35
Innsbruck, 6020
Austria
E-mail: Christian.bach@uibk.ac.at
For information on prices and availability of reprints, call 410-494-4994 X226

MATERIALS AND METHODS

Three independent observers evaluated the R/L ratio of the talar dome on the true lateral radiographs[3,4] of 51 patients (59 feet). Twenty-one patients with 29 idiopathic clubfoot deformities and 30 patients without any foot-related disease were included in the study. The patients with clubfoot had operative treatment of their feet more than 20 years before the radiographs were taken. A true lateral radiograph was obtained by putting the foot on a level surface and rotating it medially to superimpose the medial and lateral malleoli to project the talus in the true lateral projection. Because it has been suggested that the expertise of the observers can affect interobserver agreement,[15,23] only observers who had similar training and clinical experience were asked to participate the study. The observers were experienced in evaluating radiographs of patients with clubfoot deformities. All observers had training to become familiar with the measurement devices, all were provided with an illustration and a description of the R/L ratio (Figure 1), and all were given similar instructions about how the R/L ratio should be measured. The R/L index is the ratio of the radius of the curvature of the talar dome to the length of the talar bone from its posterior extremity to the distal portion of the head (Figure 1). After the first review had started, no questions or discussions were allowed during or after testing. The observers were given as much time as they needed to review each radiograph. The radiographs were classified by each observer on three separate occasions, 1 month apart. In the interim, the radiographs were not available to any of the observers and no feedback was provided. All identifying data on the radiographs were obscured, and the radiographs were numbered randomly. Each examiner recorded his measurements of the radius of the talar trochlea, the length of the talus, and the R/L ratio without knowledge of the measurements that he had made 1 month previously. All measurements were done with the original digital radiographs stored in an electronic database to avoid the loss of quality that can result from duplication. The radius of trochlear curvature and the length of the talus were determined by electronic graphical measuring devices that allowed creation of circles to measure the curvature of the trochlea of the talus and straight lines to measure the length of the talus. The position of the circles and lines and the radius of the circles could be continuously adjusted to achieve an appropriate fit. Once the observer was satisfied with the positioning, the radius of the circle and the length of the line were computed automatically, and the observer noted the measurements in a protocol. The flatter the talar dome and the shorter the overall length of the talus, the higher is the R/L ratio. The normal range for the R/L ratio was reported to be 0.365 mm with a standard deviation of 0.045 mm.[10,11]

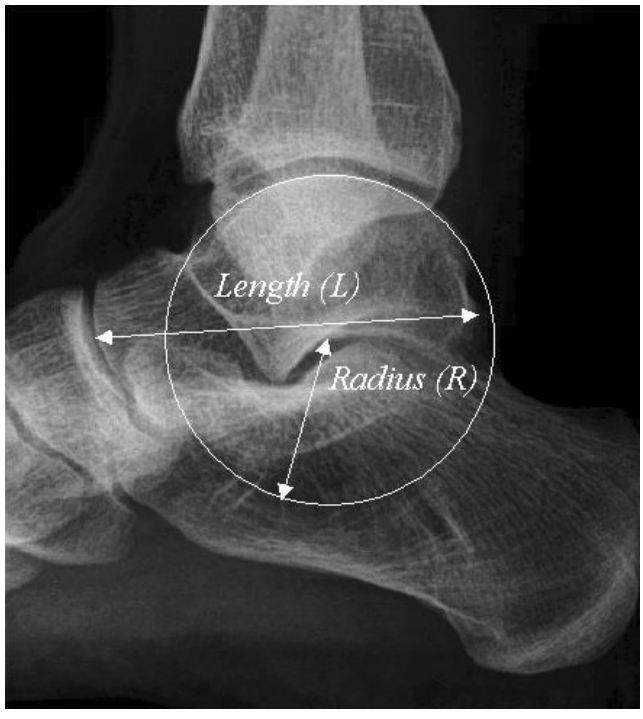

Fig. 1: The radius/length (R/L) ratio, an index of talar flattening, was determined by measuring the radius (R) of trochlear curvature of the talar dome and the length (L) of the talus from its posterior extremity to the distal portion of the head.

Statistical Analysis

A comprehensive, nonparametric correlation analysis was performed on R (radius) and L (length) values. For assessment of intraobserver reproducibility and interobserver reliability pairwise Kendall-Tau correlation coefficients were calculated. Multiple comparisons where made using Bonferroni correction. Correlations concerning R values were calculated independently for measurements with a radius of less than 45 mm and more than 45 mm. Statistical analysis was performed using SPSS 9.0 software package (SPSS for Windows, Version 9.0; SPSS, Chicago, Illinois), with statistical significance defined as $p < 0.05$.

RESULTS

Group Comparisons

No statistically significant clinical differences were noted between the patients with clubfoot and the controls with respect to age, gender, or the involved side ($p < 0.05$ each). The patients with clubfoot had a shorter talar length but a longer radius of the talar trochlea and, therefore, a reduced R/L ratio compared to the control group (Tables 1 and 2).

Table 1: Mean values of three reviews for observer 1, 2, and 3 (control group)

	Length (mm)	Radius (mm)	Radius/Length Ratio
Observer 1			
Mean +/− Standard deviation	67+/−12	25+/−5	0.37+/−0.04
Maximum	84	35	0.5
Minimum	43	14	0.3
Observer 2			
Mean +/− Standard deviation	69+/−12	24+/−4	0.35+/−0.03
Maximum	84	31	0.4
Minimum	43	14	0.3
Observer 3			
Mean +/− Standard deviation	69+/−12	27+/−5	0.39+/−0.05
Maximum	84	36	0.5
Minimum	41	16	0.3
Total			
Mean	69+/−12	25+/−5	0.37+/−0.04
Maximum	84	34	0.5
Minimum	42	15	0.3

Table 2: Mean values of three reviews for observer 1, 2, and 3 (patients with clubfeet)

	Length (mm)	Radius (mm)	Radius/Length Ratio
Observer 1			
Mean +/− Standard deviation	52+/−7	35+/−23	0.7+/−0.5
Maximum	70	99	2.3
Minimum	38	14	0.3
Observer 2			
Mean +/− Standard deviation	52+/−4	27+/−14	0.5+/−0.3
Maximum	62	83	1.4
Minimum	40	11	0.3
Observer 3			
Mean +/− Standard deviation	52+/−6	43+/−36	0.9+/−0.8
Maximum	65	144	3.2
Minimum	31	11	0.3
Total			
Mean	52+/−6	35+/−24	0.7+/−0.5
Maximum	66	108	2.3
Minimum	36	12	0.3

Reproducibility and Reliability of the R/L Ratio for the Control Group

The mean intraobserver reproducibility correlation coefficient for the length of the talus was 0.98 (range, 0.94 to 1), and the mean interobserver reliability correlation coefficient was 0.96 (range, 0.92 to 0.98). The mean intraobserver reproducibility correlation coefficient for the radius was 0.94 (range 0.82 to 0.99), and the mean interobserver reliability correlation coefficient was 0.87 (range 0.77 to 0.93). The plot graphically shows the correlation of the three reviews of observer 1 (Figure 2) and the correlation of the three observers of the first review for the measurements of the radius (Figure 3).

Reliability and Reproducibility of the R/L Ratio for the Patients with Idiopathic Clubfoot

The mean intraobserver reproducibility correlation coefficient for the length of the talus was 0.96 (range 0.92 to 0.98), and the mean interobserver reliability

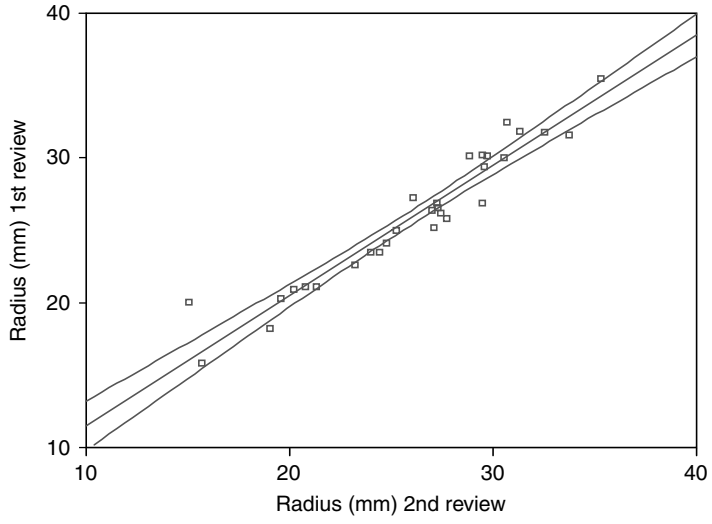

Fig. 2: Measurement of the radius of the trochlea in the controls: plot of the individual measurements of the three reviews of observer 1. The mean correlation coefficient was 0.94. The mean and the 95% confidence interval are indicated.

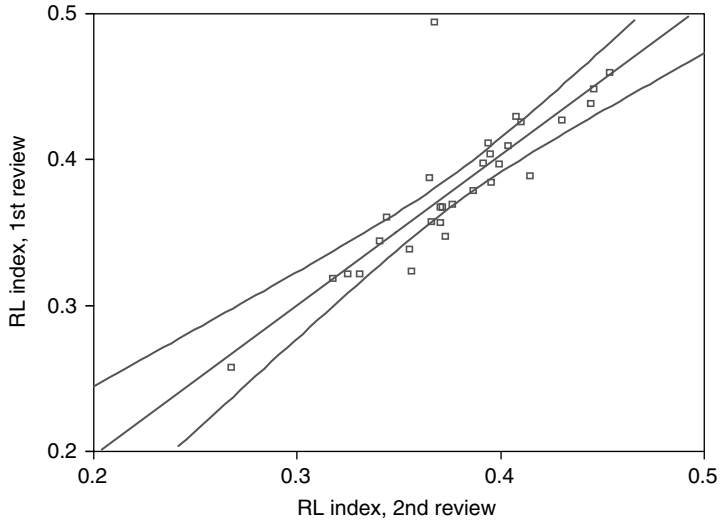

Fig. 3: Measurements of the radius of the trochlea in the controls: plot of the individual measurements of the three observers for the first review. The mean correlation coefficient was 0.89. The mean and the 95% confidence interval are indicated.

correlation coefficient was 0.88 (range 0.83 to 0.96). Plots of data points of the individual radius measurements of the three observers showed an increase of scatter with a limiting value of 45 mm for the radius of the trochlea of the talus (Figure 4 and 5). This was confirmed by the statistical analysis. In subjects with a radius of less than 45 mm the mean intraobserver reproducibility correlation coefficient was 0.74 (range 0.54 to 0.83), and the mean interobserver reliability correlation coefficient was 0.58 (range, 0.49 to 0.75). In subjects with a radius of more than 45 mm, no significant intraobserver or interobserver correlation coefficient was found ($p > 0.05$, each). The results of the individual measurements of the three observers and the three reviews are shown in Tables 3 and 4.

DISCUSSION

The results indicate that the R/L index is a reliable and reproducible measurement to assess the curvature of the trochlea of the talus in normal feet. In patients with clubfoot it was shown that the index was reliable if the radius of the trochlea of the talus was less than 45 mm. Severe degrees of talar flattening were not reliably and reproducibly measured by the R/L index, suggesting that the R/L index should not be used if the radius of the trochlea of the talus exceeds 45 mm.

Radiographic technique is important for an appropriate assessment of the R/L index. In a clubfoot the talus is externally rotated in relation to the forefoot and

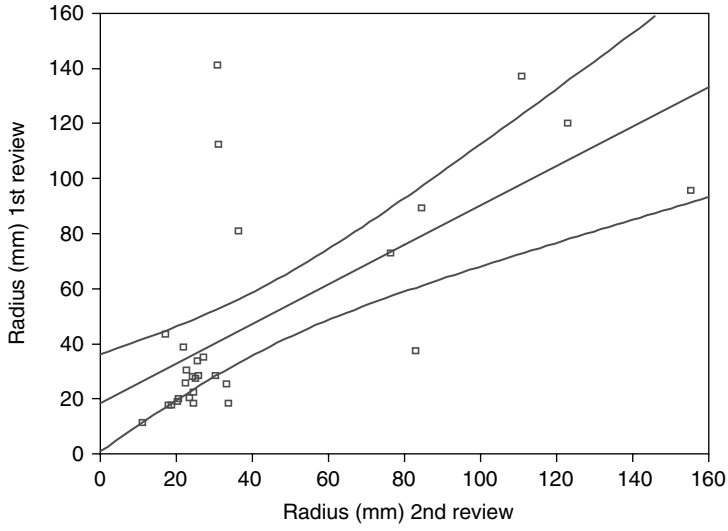

Fig. 4: Measurement of the radius of the trochlea of the talus in patients with clubfoot: plot of the individual measurements of the three reviews of observer 1. For radial measurements of more than 45 mm the plot increases and the correlation between the measurements was not statistically significant ($p > 0.05$). The mean and the 95% confidence interval are indicated.

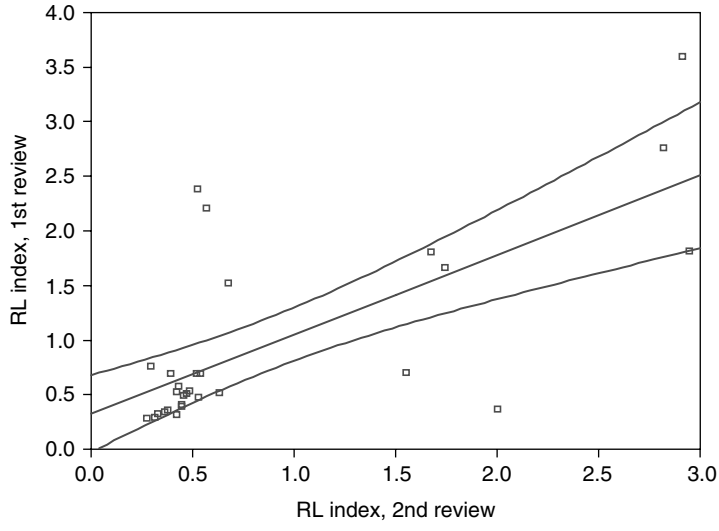

Fig. 5: Measurements of the radius of the trochlea of the talus in patients with clubfoot: plot of the individual measurements of the three observers for the first review. For measurements of more than 45 mm the plot increases and the correlation between the measurements was not statistically significant ($p > 0.05$). The mean and the 95% confidence interval are indicated.

the tibia, so that a routine lateral radiograph of the foot has an oblique projection of the talus. The two dome-shaped sides of the trochlea of the talus may project separately and give the appearance of flattening that is not real, or the actual loss of convexity of the trochlea may be exaggerated. Radiographs of a clubfoot made with the foot sufficiently medially rotated depicts the talus in a true lateral projection.[30] The true lateral anatomy of the talus is best demonstrated with the foot medially rotated sufficiently to superimpose the medial and lateral malleoli.[3,4]

Because the R/L index was unreliable if the radius exceeded 45 mm, the radiographs of patients with this criterion were reviewed to identify possible reasons for the intrinsic error. It was found that in most patients with severe flattening of the dome, growth disturbances had affected different parts of the talus and therefore flattening was not the same in all parts of the dome, making it difficult to measure the curvature with one single radius. Additionally, in some patients with severe flattening a radius of up to 11 cm was measured. These radiographs had to be scaled down to allow appropriate measurements. The evaluation of the curvature on the smaller picture might have contributed to the high variations in the intraobserver and interobserver measurements.

Table 3: Intraobserver and interobserver correlation for a radius of the trochlea of the talus less than 45 mm (patients with clubfeet)

Radius	1st review versus 2nd review	1st review versus 3rd review	2nd review versus 3rd review
	pairwise Kendall-Tau correlation coefficient		
Observer 1	0.79	0.73	0.79
Observer 2	0.76	0.83	0.78
Observer 3	0.73	0.54	0.73
	Observer 1 versus Observer 2	**Observer 1 versus Observer 3**	**Observer 2 versus Observer 3**
	pairwise Kendall-Tau correlation coefficient		
1st review	0.41	0.61	ns
2nd review	0.49	0.67	0.68
3rd review	0.57	0.75	0.47

Table 4: Intraobserver and interobserver correlation for the length of the talus (patients with clubfeet)

Length	1st review versus 2nd review	1st review versus 3rd review	2nd review versus 3rd review
	pairwise Kendall-Tau correlation coefficient		
Observer 1	0.96	0.97	0.97
Observer 2	0.96	0.94	0.98
Observer 3	0.92	0.94	0.98
	Observer 1 versus Observer 2	**Observer 1 versus Observer 3**	**Observer 2 versus Observer 3**
	pairwise Kendall-Tau correlation coefficient		
1st review	0.89	0.96	0.90
2nd review	0.86	0.91	0.85
3rd review	0.83	0.92	0.84

We tried to find a geometrical method to approximate severe flattening but found no system that could be recommended for clinical practice. Others also failed to devise a geometrical method of evaluating and assigning a numerical value to the curvature because of the gross irregularity and variability of the curve in severe cases.[4] One factor that must be considered when evaluating the data is that all examiners were aware of the purpose of their measurements, and some may have tried to improve their precision. In this sense, the study does not simulate a real–life situation, and it is likely that the results in clinical practice are less precise. It is also important to emphasize that this study quantitated only intrinsic error. In a clinical setting, two radiographs made at different times are measured. This allows for the introduction of extrinsic error, for which the main sources are the position of the patient and the position of the radiographic tube.

It also should be considered that the R/L index is not independent from the shape of the talar head and neck. A short talar neck decreases the length of the talus and a flattened talar head increases the radius, which would increase the R/L index and give an apparent flattening that is not real.

The current results indicate that the R/L ratio of talar flattening is reliable and reproducible for mild talar deformity. In patients with clubfoot it was shown that the index was reliable if the radius of the trochlea of the talus was less than 45 mm. Severe degrees of talar flattening could not be reliably and reproducibly measured by the R/L index, and it should not be used if the radius of the trochlea of the talus exceeds 45 mm.

REFERENCES

1. **Aplington, JP; Riddle Jr, CD:** Avascular necrosis of the body of the talus after combined medial and lateral release of congenital clubfoot. Southern Med. J. **69**:1037–1038, 1976.
2. **Cooper, DM; Dietz, FR:** Treatment of idiopathic clubfoot. A thirty-year follow-up note. J. Bone Joint Surg. **77-A**:1477–1489, 1995.
3. **Cummings, RJ; Bashore, CJ; Bookout, CB; Elliott, MJ:** Avascular necrosis of the talus after McKay clubfoot release for idiopathic congenital clubfoot. J. Pediatr. Orthop. **21**:221–224, 2001.
4. **Dunn, HK; Samuelson, KM:** Flat-top talus. A long-term report of twenty club feet. J. Bone Joint Surg. **56-A**:57–62, 1974.
5. **Flikkila, T; Nikkola-Sihto, A; Kaarela, O; Paakko, E; Raatikainen, T:** Poor interobserver reliability of AO classification of fractures of the distal radius. Additional computed tomography is of minor value. J. Bone Joint Surg. **80-B**:670–672, 1998.
6. **Frandsen, PA; Andersen, E; Madsen, F; Skjodt, T:** Garden's classification of femoral neck fractures. An assessment of inter-observer variation. J. Bone Joint Surg. **70-B**:588–590, 1988.
7. **Franke, J; Hein, G:** Our experience with the early operative treatment of congenital clubfoot. J. Pediatr Orthop. **8**:26–30, 1988.
8. **Ghali, NN; Smith, RB; Clayden, AD; Silk, FF:** The results of pantalar reduction in the management of congenital talipes equinovarus. J. Bone Joint Surg. **65-B**:1–7, 1983.
9. **Haasbeek, JF; Wright, JG:** A comparison of the long-term results of posterior and comprehensive release in the treatment of clubfoot. J. Pediatr Orthop. **17**:29–35, 1997.
10. **Hjelmstedt, A; Sahlstedt, B:** Simultaneous arthrography of the talocrural and talonavicular joints in children. IV. Measurements on congenital club feet. Acta Radiol.[Diagn] (Stockh). **19**:223–236, 1978.
11. **Hjelmstedt, EA; Sahlstedt, B:** Arthrography as a guide in the treatment of congenital clubfoot. Findings and treatment results in a consecutive series. Acta Orthop. Scand. **51**:321–334, 1980.
12. **Hutchins, PM; Foster, BK; Paterson, DC; Cole, EA:** Long-term results of early surgical release in club feet. J. Bone Joint Surg. **67-B**:791–799, 1985.
13. **Irani, RN; Sherman, MS:** The pathological anatomy of clubfoot. J. Bone Joint Surg. **45-A**:45–52, 1963.
14. **Keim, HA; Ritchie, GW:** ''Nutcracker'' treatment of clubfoot. JAMA. **189**:613–615, 1964.
15. **Kristiansen, B; Andersen, UL; Olsen, CA; Varmarken, JE:** The Neer classification of fractures of the proximal humerus. An assessment of interobserver variation. Skeletal Radiol. **17**:420–422, 1988.
16. **Kumar, PN; Laing, PW; Klenerman, L:** Medial calcaneal osteotomy for relapsed equinovarus deformity. Long- term study of the results of Frederick Dwyer. J. Bone Joint Surg. **75-B**:967–971, 1993.
17. **Lau, JH; Meyer, LC; Lau, HC:** Results of surgical treatment of talipes equinovarus congenita. Clin. Orthop. **248**:219–226, 1989.
18. **Miller, JH; Bernstein, SM:** The roentgenographic appearance of the ''corrected clubfoot''. Foot Ankle Int. **6**:177–183, 1986.
19. **Napiontek, M:** Clinical and radiographic appearance of congenital talipes equinovarus after successful nonoperative treatment. J. Pediatr Orthop. **16**:67–72, 1996.
20. **Nielsen, JO; Dons-Jensen, H; Sorensen, HT:** Lauge-Hansen classification of malleolar fractures. An assessment of the reproducibility in 118 cases. Acta Orthop. Scand. **61**:385–387, 1990.
21. **Ponseti, IV; El Khoury, GY; Ippolito, E; Weinstein, SL:** A radiographic study of skeletal deformities in treated clubfeet. Clin. Orthop. **160**:30–42, 1981.
22. **Porat, S; Kaplan, L:** Critical analysis of results in club feet treated surgically along the Norris Carroll approach: seven years of experience. J. Pediatr. Orthop. **9**:137–143, 1989.
23. **Rasmussen, S; Madsen, PV; Bennicke, K:** Observer variation in the Lauge-Hansen classification of ankle fractures. Precision improved by instruction. Acta Orthop. Scand. **64**:693–694, 1993.
24. **Rumyantsev, NJ; Ezrohi, VE:** Complete subtalar release in resistant clubfeet: a critical analysis of results in 146 cases. J. Pediatr Orthop. **17**:490–495, 1997.
25. **Sahlstedt, B:** Arthrographic analysis of the congenital clubfoot. Proceedings of the Scandinavian Orthopaedic Society. Acta Orthop. Scand. **45**:955, 1974.
26. **Settle, GW:** The anatomy of the congenital talipes equino-varus: Sixteen dissected specimens. J. Bone Joint Surg. **45-A**:1341–1353, 1963.
27. **Sidor, ML; Zuckerman, JD; Lyon, T; et al.:** The Neer classification system for proximal humeral fractures. An assessment of interobserver reliability and intraobserver reproducibility. J. Bone Joint Surg. **75-A**:1745–1750, 1993.
28. **Siebenrock, KA; Gerber, C:** The reproducibility of classification of fractures of the proximal end of the humerus. J. Bone Joint Surg. **75-A**:1751–1755, 1993.
29. **Smith, SW; Meyer, RA; Connor, PM; Smith, SE; Hanley, EN:** Interobserver reliability and intraobserver reproducibility of the modified Ficat classification system of osteonecrosis of the femoral head. J. Bone Joint Surg. **78-A**:1702–1706, 1996.
30. **Swann, M; Lloyd-Roberts, GC; Catterall, A:** The anatomy of uncorrected club feet. A study of rotation deformity. J. Bone Joint Surg. **51-B**:263–269, 1969.
31. **Thomsen, NO; Overgaard, S; Olsen, LH; Hansen, H; Nielsen, ST:** Observer variation in the radiographic classification of ankle fractures. J. Bone Joint Surg. **73-B:**676–678, 1991.