Thomas Rettenbacher, MD
Alois Hollerweger, MD
Peter Macheiner, MD
Norbert Gritzmann, MD
Martin Daniaux, MD
Klaus Schwamberger, MD
Hanno Ulmer, PhD
Dieter zur Nedden, MD

# Ovoid Shape of the Vermiform Appendix: A Criterion to Exclude Acute Appendicitis—Evaluation with US[1]

**Index terms:**
Appendicitis, 751.291
Appendix, US, 751.12981

**Published online before print**
10.1148/radiol.2261011496
**Radiology 2003;** 226:95–100

[1] From the Department of Radiology II, University Hospital Innsbruck, Anichstrasse 35, 6020 Innsbruck, Austria (T.R., M.D., D.z.N.); Departments of Radiology (A.H., P.M., N.G.) and Surgery (K.S.), Hospital Barmherzige Brueder, Salzburg, Austria; and Institute of Biostatistics, University of Innsbruck, Austria (H.U.). From the 1999 RSNA scientific assembly. Received September 7, 2001; revision requested November 9; final revision received April 9, 2002; accepted April 30. **Address correspondence to** T.R. (e-mail: *thomas.rettenbacher@uklibk.ac.at*).

**Author contributions:**
Guarantors of integrity of entire study, T.R., K.S., N.G., D.z.N., H.U.; study concepts, T.R., A.H., D.z.N.; study design, T.R., M.D.; literature research, T.R., A.H., M.D.; clinical studies, T.R., A.H., P.M., N.G.; data acquisition, T.R., A.H., P.M.; data analysis/interpretation, T.R., K.S., N.G.; statistical analysis, T.R., H.U., M.D.; manuscript preparation, T.R.; manuscript definition of intellectual content, T.R., A.H., D.z.N.; manuscript editing, T.R.; manuscript revision/review, T.R., P.M., M.D.; manuscript final version approval, A.H., N.G., D.z.N., K.S., H.U.



**PURPOSE:** To investigate whether the shape of the appendix in transverse section may be considered an ultrasonographic (US) criterion to exclude or confirm acute appendicitis.

**MATERIALS AND METHODS:** The shapes of appendices of 100 control subjects, of 174 patients with clinical suspicion of acute appendicitis but without acute appendicitis, and of 108 patients with acute appendicitis were prospectively evaluated with US. Definite diagnoses in patients with clinical suspicion of acute appendicitis were established and confirmed either with surgery and histologic examination in 161 patients or with clinical follow-up in 121 patients. Statistical measures such as sensitivity, specificity, positive and negative predictive values, and accuracy were assessed for the appendiceal shape as a diagnostic US criterion for acute appendicitis.

**RESULTS:** An at least partly round appendix indicated acute appendicitis with a sensitivity of 100%; specificity of 37%; positive and negative predictive values of 50% and 100%, respectively; and accuracy of 61%. In 67 of 174 patients with clinical suspicion of acute appendicitis but without acute appendicitis, the partly ovoid appendiceal shape aided in the exclusion of acute appendicitis, since it indicated a normal appendix with a probability of 86%. In 65 of 174 patients with clinical suspicion of acute appendicitis but without acute appendicitis, the ovoid shape over the entire appendiceal length excluded acute appendicitis with confidence.

**CONCLUSION:** The shape of the appendix in transverse section is a useful US criterion, since an ovoid shape over the entire appendiceal length reliably rules out acute appendicitis.



At ultrasonography (US), the transverse section of the vermiform appendix appears either round or ovoid. About 10 years ago, we observed that acutely inflamed appendices are round in most cases and normal appendices are often ovoid. Before the present study was initiated, we routinely used the appendiceal shape along with various other signs as an additional diagnostic US criterion to exclude acute appendicitis. Literature research showed only one publication that mentioned that normal appendices appear ovoid in the transverse plane (1). However, we did not find publications using the appendiceal shape as a diagnostic criterion to confirm or exclude acute appendicitis, nor were percentages of occurrence given. Therefore, the purpose of our study was to prospectively evaluate whether the shape of the appendix in transverse section may be considered a US criterion to exclude or confirm acute appendicitis.

## MATERIALS AND METHODS

### Patient Population

In this prospective study, 484 individuals underwent US of the vermiform appendix. Informed consent was obtained from each person, and the study was approved by the

ethics committee at our hospital. The 484 individuals consisted of two groups: 147 control subjects and 337 patients clinically suspected of having acute appendicitis.

*Control subjects*.—In 100 of 147 consecutive adult control subjects (age range, 26–82 years; mean age, 53 years), the US investigators were able to visualize the appendix and then prospectively assess the shape of the appendiceal transverse section in all US-depicted appendices. The control subjects were part of an abdominal US screening program, which has been offered to inpatients as common practice, even to those patients without clinical abdominal symptoms. The selection criterion was that the patients did not exhibit any sign of abdominal disease. In preparation for the general screening investigation, the subjects fasted overnight. At the end of the screening investigation, we attempted to detect the appendix at US within an examination time of 5–15 minutes.

*Patients clinically suspected of having acute appendicitis*.—During the study period of approximately 3 years, 337 of 355 consecutive patients with clinical suspicion of acute appendicitis (age range, 7–97 years; mean age, 35 years) underwent a diagnostic US investigation as common practice. Eighteen of 355 patients underwent surgery without diagnostic imaging because they were admitted during the night and had a clinical presentation that was typical for acute appendicitis. In 282 of 337 patients who were clinically suspected of having acute appendicitis, the investigators were able to detect the appendix at US and then prospectively assess the shape of the appendiceal transverse section.

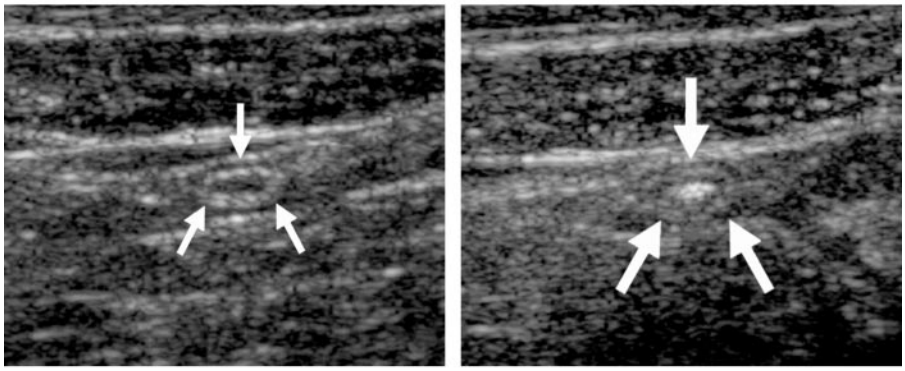

a. b.

**Figure 1.** Normal appendix, ovoid shape. **(a)** US image shows the transverse section (arrows) of the proximal portion of a normal vermiform appendix. The appendiceal cavity is empty, and the shape appears ovoid. **(b)** US image shows the transverse section (arrows) of the distal portion of the same appendix as in **a.** The appendiceal cavity contains gas, and the shape appears ovoid.

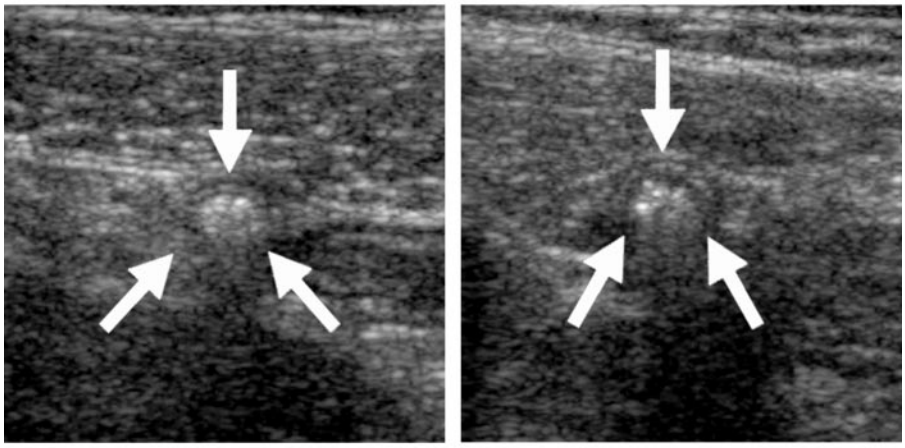

a. b.

**Figure 2.** Normal appendix, round shape. **(a)** US image shows the transverse section (arrows) of the proximal portion of a normal vermiform appendix. The appendiceal cavity is filled with feces and air, and the shape appears round. **(b)** US image shows the transverse section (arrows) of the distal portion of the same appendix as in **a.** The appendiceal cavity is filled with feces and air, and the shape appears round.

## Imaging Equipment

For US, commercially available equipment, including a US unit with C4-2 MHz, L7-4 MHz, and L10-5 MHz transducers (HDI 3000; Advanced Technology Laboratories, Bothell, Wash) and a US unit with C5.0-3.5 MHz and L10.0-7.5 MHz transducers (AU4; Esaote, Florence, Italy), were used. Four radiologists (T.R., A.H., P.M., N.G.) highly experienced in gastrointestinal US performed all diagnostic examinations.

## Image Evaluation

For the assessment of appendiceal shapes at US, only appendiceal transverse sections were used. For this purpose, the smallest outer diameter, which is usually the anteroposterior one, and the largest outer diameter, which is usually perpendicular to the smallest one, were assessed. To measure outer appendiceal diameters, electronic calipers were placed between the outer borders of the hypoechoic tunica muscularis. This was performed by the investigating radiologist during the US examination. The US images were documented by using a multiformat camera, and the results were noted in a protocol immediately after imaging. An appendiceal transverse section was interpreted as ovoid if the difference between the smallest and largest diameters was greater than 1 mm. Since a normal or acutely inflamed appendix can have different diameters and shapes throughout its length, several measurements of a given appendix were performed and noted in a protocol. In the case of a partially acutely inflamed appendix, surgical and histologic reports included information on which appendiceal portion was not affected by or was less affected by inflammation. Therefore, appendiceal shapes and surgical and histologic results of different appendiceal portions could be compared.

In obese patients, the increased distance between the US transducer and the ileocecal region reduced the appendiceal detection rate in our study by impairing the image quality and by decreasing the success rate of high-frequency US transducers. In addition, if the cecum was located in the true pelvis or in an atypical

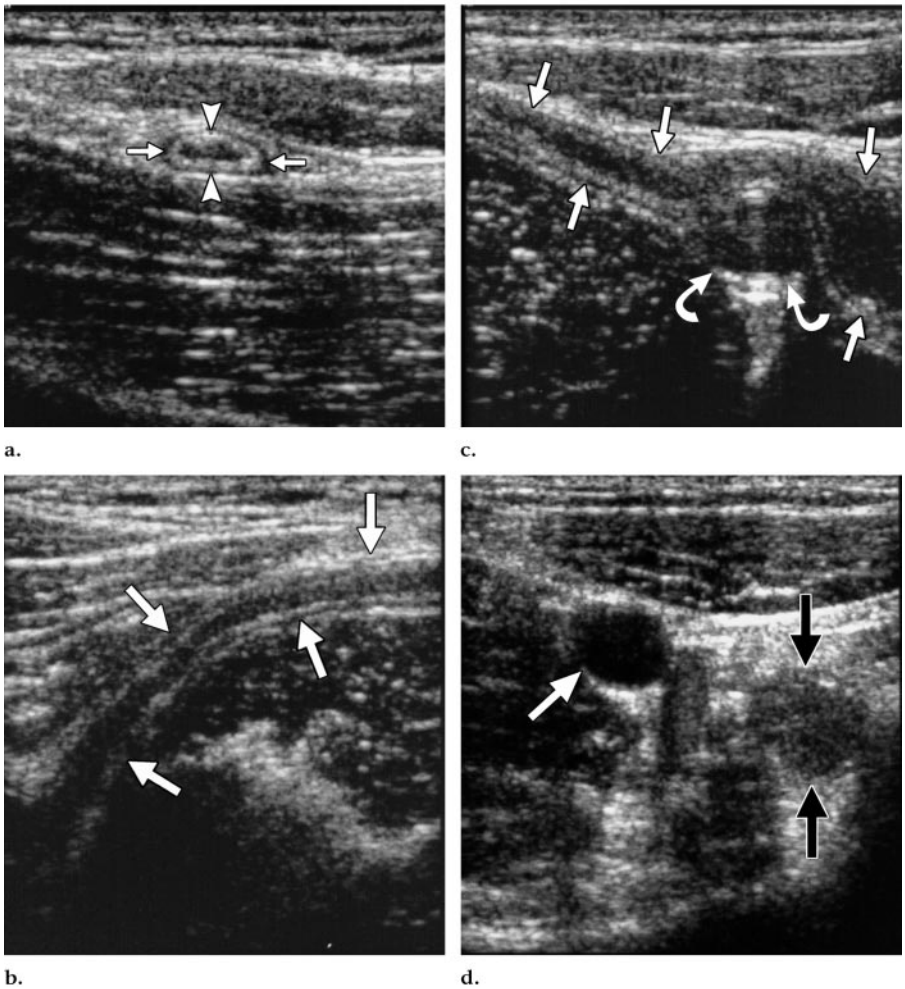


**Figure 3.** Normal appendix, ovoid and round shape. **(a)** US image shows the ovoid transverse section (arrows and arrowheads) of the proximal portion of a normal appendix. The appendiceal cavity is empty and collapsed. Appendiceal compressibility could not be demonstrated, since the anteroposterior diameter (arrowheads) could not be decreased. **(b)** US image shows the longitudinal section (arrows) of the proximal portion, which is located between the abdominal wall and the psoas muscle, in the same appendix as in **a**. **(c)** US image shows the longitudinal section (straight arrows) of the distal portion, which extends over the iliac artery (curved arrows) into the true pelvis, in the same appendix as in **a**. **(d)** US image shows the transverse section (black arrows) of the distal portion, which is located in the true pelvis, in the same appendix as in **a**. That part of the appendix is filled with fluid and is round. Compressibility could not be demonstrated because the appendix could not be compressed against a fixed anatomic structure. White arrow indicates the right iliac artery.

position, the appendiceal detection rate was reduced. If the appendix was not detectable and none of the above-mentioned reasons were present, we assumed that the appendix was probably located retrocecally. Therefore, we defined and assessed three reasons for nondetectability of the appendix at US as follows: obesity, cecum located in the true pelvis or in an atypical position, and appendix located retrocecally. If an appendix was not detectable at US in our study, the investigator had to identify one of the above three reasons during the US investigation and record it in a protocol immediately after imaging.

### Reference Standard

Of the 282 patients clinically suspected of having acute appendicitis in whom the appendix was depicted and evaluated at US, 108 had acute appendicitis and 174 did not. The diagnosis in all 108 patients with acute appendicitis was confirmed at surgery and histologic examination. In the 174 patients without acute appendicitis, diagnosis was confirmed at surgery and histologic examination in 53 patients and at clinical follow-up in 121 patients. Clinical follow-up consisted of symptom resolution during the hospital stay and its confirmation by means of telephone at least 8 weeks after hospitalization.

### Statistical Analysis

Sensitivity, specificity, positive and negative predictive values, and accuracy were calculated by using $2 \times 2$ contingency tables. These statistical measures were assessed for a round shape over the entire appendiceal length and for an at least partly round appendix as a criterion for acute appendicitis.

The Pearson $\chi^2$ test was used to compare the frequencies of the appendiceal shapes between the control subjects, the patients without acute appendicitis, and those with acute appendicitis in pairs. $P$ values less than .05 were considered to indicate a statistically significant difference.

Data analyses were performed with the statistical software package SAS version 8.0 (SAS Institute, Cary, NC) for Windows (Microsoft, Redmond, Wash).

## RESULTS

In 37 (37%) of 100 control subjects, the appendix was ovoid over the entire appendiceal length; in 30 subjects (30%), it was round over the entire length; and in 33 subjects (33%), the appendix was both ovoid and round, since it was not uniform over the entire appendiceal length. In 65 (37%) of 174 patients with right lower-quadrant pain without having acute appendicitis, the appendix was ovoid over its entire length (Fig 1); in 42 patients without acute appendicitis (24%), it was round over the entire length (Fig 2); and in 67 patients without acute appendicitis (39%), it was both ovoid and round (Fig 3). The appendiceal shapes of acutely inflamed appendices were never only ovoid. They were only round in 87 (81%) of 108 patients (Fig 4) and were ovoid and round in 21 (19%) of 108 patients. Fifteen (71%) of 21 patients with a partly ovoid acutely inflamed appendix had the ovoid shape in the proximal portion of the appendix, which was not affected by (nine patients) or was less affected by (six patients) the inflammation at histologic examination. An overview referring to the proportion of appendiceal shapes in control subjects and patients with clinical suspicion of acute appendicitis who either had acute appendicitis or did not is shown in Figure 5.

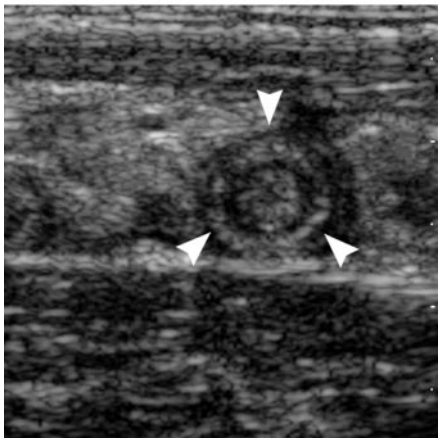

**Figure 4.** Acute appendicitis, round shape. US image shows the transverse section (arrowheads) of an acutely inflamed appendix that appears round.

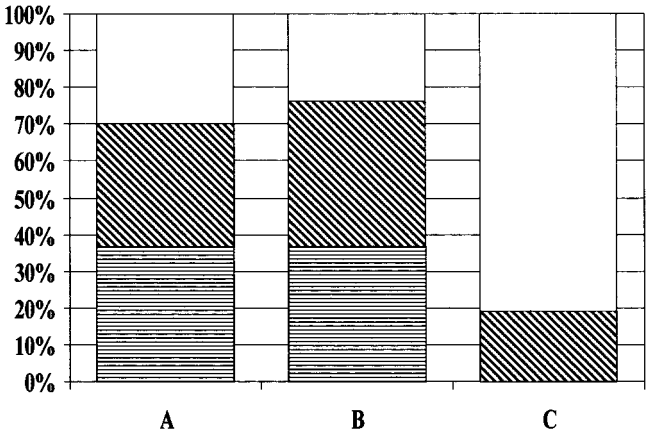


**Figure 5.** Graph illustrates the proportion of appendiceal shapes. Horizontally striped areas are for appendices that are ovoid over their entire length. Diagonally striped areas are for appendices that are partly ovoid and partly round. White areas are for appendices that are round over their entire length. Column *A* represents 100 control subjects; column *B*, 174 patients with clinical suspicion of acute appendicitis without having acute appendicitis; and column *C*, 108 patients with acute appendicitis. Each patient group is 100%.

A round shape over the entire appendiceal length as a finding positive for acute appendicitis had a sensitivity of 81% (87 of 108 patients); specificity of 76% (132 of 174 patients); positive and negative predictive values of 67% (87 of 129 patients) and 86% (132 of 153 patients),respectively; and accuracy of 78% (219 of 282 patients).

An at least partly round appendix as a finding positive for acute appendicitis had a sensitivity of 100% (108 of 108 patients); specificity of 37% (65 of 174 patients); positive and negative predictive values of 50% (108 of 217 patients) and 100% (65 of 65 patients), respectively; and accuracy of 61% (173 of 282 patients).

There was a highly significant difference with regard to appendiceal shapes between the control subjects and the patients with acute appendicitis, as well as between the patients with clinical suspicion of appendicitis without having acute appendicitis and the patients with acute appendicitis ($P < .001$). There was no statistically significant difference between the control subjects and the patients with clinical suspicion of appendicitis without having acute appendicitis ($P = .51$).

In 67 (39%) of 174 patients with right lower-quadrant pain and without acute appendicitis, the partly ovoid appendiceal shape (Fig 3) aided in the exclusion of acute appendicitis, since it indicated a normal appendix with a probability of 86%.

In 65 (37%) of 174 patients with right lower-quadrant pain and without acute appendicitis, the ovoid shape over the entire appendiceal length (Fig 1) allowed for the exclusion of acute appendicitis with confidence (specificity, 100%).

In 100 of 147 control subjects, the appendix could be visualized with US (detection rate, 68%). The reasons and frequencies of occurrence of nondetectability of the appendix were as follows: obesity in 17 (36%) of 47 control subjects, cecum located in the true pelvis or in an atypical position in 14 control subjects (30%), and appendix located retrocecally in 16 control subjects (34%).

In 174 of 226 patients with clinical suspicion of acute appendicitis but without appendicitis, the appendix could be visualized with US (detection rate, 77%). The reasons for and frequencies of nondetectability of the appendix were as follows: obesity in 21 (40%) of 52 patients, cecum located in the true pelvis or in an atypical position in 15 patients (29%), and appendix located retrocecally in 16 patients (31%).

In 108 of 111 patients with acute appendicitis, the appendix could be visualized with US (detection rate, 97%). One patient was too obese to allow detection of the appendix, and in the other two patients, the reason for nondetectability was the fact that the cecum was located in the true pelvis.

## DISCUSSION

To our knowledge, this is the first study in which the shape of the appendiceal transverse section was investigated as a diagnostic US criterion to confirm or exclude acute appendicitis.

Why should the appendix appear either round or ovoid at the transverse section? The vermiform appendix is a wormlike gastrointestinal organ with a cavity that is connected to the cecum. The cavity can be either empty or filled with gas and/or feces and/or fluid. In the case of an empty appendiceal cavity, the appendix is collapsed and the transverse section tends to appear ovoid, whereas a filled cavity results in a more rounded appendiceal shape. At acute inflammation, all appendiceal wall layers are rapidly affected, and as a result, a marked thickening of the appendiceal wall usually occurs. The wall thickening causes an increase of the outer appendiceal diameter and a rounding of the shape.

We regard it as important to emphasize that the appendiceal shape as a diagnostic US sign as described in the present study is not the same as appendiceal compressibility, which is an important and established US criterion. The appendiceal compressibility can be defined as a noticeable shortening of the anteroposterior appendiceal diameter during application of moderate pressure with the US transducer. From a practical point of view, the compressibility can be proved on the appendiceal transverse section, which changes its shape from round to ovoid or from ovoid to a more pronounced ovoid shape. Most US studies used this sign as an important criterion,

usually in addition to one or several other criteria (1–22). However, our search found no study in the literature that gave percentages of occurrence in normal and acutely inflamed appendices, which would allow for the evaluation of this criterion. One reason for this is certainly that this US sign was introduced in the late 1980s. At that time, the normal appendix was not or was seldom detectable at US (21–26), thus preventing the evaluation of this criterion in normal appendices. Therefore, the sign of appendiceal compressibility was predominantly based on the observation that an acutely inflamed appendix is not usually compressible during application of moderate pressure with the US transducer. This is in accordance with our observations. However, we also observed that normal appendices are often not compressible or that the compressibility cannot be proved.

For example, the proximal portion or the whole length of the appendix is often located between the abdominal wall and the psoas muscle. In this position, the appendiceal cavity is often empty and the transverse section ovoid, even without applying any pressure with the US transducer to the abdominal wall. In this case, the compressibility cannot be proved, since the cavity is collapsed and the anteroposterior appendiceal diameter cannot be further decreased during compression. The distal portion of the appendix often extends over the iliac vessels into the true pelvis, and in that position, the normal appendiceal cavity is often filled with gas and/or feces and/or fluid and therefore is round. The compressibility in that position usually cannot be proved, since the appendix cannot be compressed against a fixed anatomic structure. In addition, a normal appendix can be so movable that it tends to disappear out of the field of view before compressibility can be demonstrated. We agree that the compressibility is an important US criterion. If it is detectable, which is infrequently the case in our experience, acute appendicitis can be excluded with high probability. Because of the limitations of the appendiceal compressibility as a US criterion to exclude acute appendicitis, we believe the appendiceal shape is a useful additional US sign in our experience. We have used it successfully in everyday practice at our hospital for about 10 years.

The discrepancy between the fact that appendiceal compressibility was one of the most frequently used US criteria in the literature, while none of the investigators studied the frequency of occurrence of compressibility in normal and acutely inflamed appendices (1–22), and our above-mentioned observation about the limitations of the compressibility led us to assume that several of the studies used both appendiceal compressibility and appendiceal shape as diagnostic criteria.

For the present study, both control subjects and patients with clinical suspicion of acute appendicitis without having acute appendicitis were included. Thus, we were able to study whether the appendiceal appearance in the control subjects and that in the patients with right lower-quadrant pain but without evidence of appendicitis resembled one another. For example, inflammatory processes located near the appendix can cause a concomitant appendiceal reaction, thus changing the appendiceal appearance at cross-sectional imaging (27, authors' observation). In addition, the study group of patients with clinical suspicion of acute appendicitis without evidence of acute appendicitis may contain some patients with spontaneously resolving appendicitis (9,28).

The results of our study showed that there was no statistically significant difference between the control subjects and the patients without appendicitis. For the calculations of sensitivity, specificity, positive and negative predictive values, and accuracy, only patients with clinical suspicion of appendicitis were considered, since the comparison with control subjects was considered clinically less relevant.

The results of our study showed that a partly or entirely round appendix indicated acute appendicitis with a high sensitivity of 100% or 81% but with a markedly low specificity of 37% or 76%. Therefore, the round appendiceal shape should not be considered a reliable criterion for acute appendicitis. However, the ovoid appendiceal shape was a reliable US sign to exclude appendicitis. The detection of a partly ovoid appendix indicated a normal appendix with a probability of 86%, and an ovoid shape over the entire appendiceal length indicated a normal appendix with a probability of 100%. Therefore, the most relevant result of our study was that the US depiction of an ovoid shape over the entire length of the appendix reliably ruled out acute appendicitis.

Why should an additional US criterion be welcome? Today, as a consequence of high cross-sectional imaging detection rates of normal appendices, it is diagnostically decisive to recognize an appendix as acutely inflamed or normal, whereas previously, normal appendices were rarely detectable. None of the established US criteria to differentiate between acutely inflamed and normal appendices have both sufficiently high sensitivity and specificity (8,11,29–33). Therefore, the US diagnosis should be based on several criteria simultaneously. These US criteria should consist of the outer appendiceal diameter, appendiceal compressibility, location of the point of tenderness, hyperechoic periappendiceal inflamed fatty tissue, appendiceal shape, gas in the appendiceal lumen, blood flow in the appendiceal wall detected at color Doppler US, and appendicoliths (8,11,21,29–34).

Can we expect the appendiceal shape to become a criterion for other cross-sectional imaging modalities like computed tomography (CT) or magnetic resonance (MR) imaging, as well? The unpredictable and often tortuous appendiceal course requires an imaging modality with the ability to effortlessly change scanning planes. US is the ideal imaging modality to gain exact transverse planes with minimal time consumption, whereas for CT or MR imaging the calculation of exact transverse planes along a unpredictable and tortuous axis would be cumbersome. Similar considerations also would be applicable for appendiceal compressibility.

It may be assumed that the obesity of the population markedly reduces the usefulness of diagnostic US if acute appendicitis is clinically suspected. Therefore, it is noteworthy that obesity was the reason for nondetectability of the appendix in only 9% (21 of 226) of patients without appendicitis and in only 1% (one of 111) of patients with appendicitis in our study, even though a considerable proportion of the Austrian population is obese. Other important reasons for nondetectability of the appendix were the location of the cecum in the true pelvis, an atypically located cecum, and the appendix located retrocecally.

In conclusion, an ovoid shape over the entire length of the vermiform appendix is a useful US criterion, since it helps to reliably rule out acute appendicitis.

**References**


1. Sivit CJ. Diagnosis of acute appendicitis in children: spectrum of sonographic findings. AJR Am J Roentgenol 1993; 161: 147–152.
2. Poljak A, Jeffrey RB Jr, Kernberg ME. The gas-containing appendix: potential sonographic pitfall in the diagnosis of acute appendicitis. J Ultrasound Med 1991; 10: 625–628.
3. Nghiem HV, Jeffrey RB Jr. Acute appendicitis confined to the appendiceal tip: eval-

uation with graded compression sonography. J Ultrasound Med 1992; 11:205–207.
4. Rioux M. Sonographic detection of the normal and abnormal appendix. AJR Am J Roentgenol 1992; 158:773–778.
5. Balthazar EJ, Birnbaum BA, Yee J, Megibow AJ, Roshkow J, Gray C. Acute appendicitis: CT and US correlation in 100 patients. Radiology 1994; 190:31–35.
6. Yacoe ME, Jeffrey RB Jr. Sonography of appendicitis and diverticulitis. Radiol Clin North Am 1994; 32:899–912.
7. Jeffrey RB, Jain KA, Nghiem HV. Sonographic diagnosis of acute appendicitis: interpretive pitfalls. AJR Am J Roentgenol 1994; 162:55–59.
8. Quillin SP, Siegel MJ. Appendicitis: efficacy of color Doppler sonography. Radiology 1994; 191:557–560.
9. Migraine S, Atri M, Bret PM, Lough JO, Hinchey JE. Spontaneously resolving acute appendicitis: clinical and sonographic documentation. Radiology 1997; 205:55–58.
10. Vermeulen B, Morabia A, Unger PF, et al. Acute appendicitis: influence of early pain relief on the accuracy of clinical and US findings in the decision to operate-a randomized trial. Radiology 1999; 210: 639–643.
11. Lim HK, Lee WJ, Kim TH, Namgung S, Lee SJ, Lim JH. Appendicitis: usefulness of color Doppler US. Radiology 1996; 201: 221–225.
12. Lessin MS, Chan M, Catallozzi M, et al. Selective use of ultrasonography for acute appendicitis in children. Am J Surg 1999; 177:193–196.
13. Galindo GM, Fadrique B, Nieto MA, et al. Evaluation of ultrasonography and clinical diagnostic scoring in suspected appendicitis. Br J Surg 1998; 85:37–40.
14. Birnbaum BA, Jeffrey RB Jr. CT and sonographic evaluation of acute right lower quadrant abdominal pain. AJR Am J Roentgenol 1998; 170:361–371.
15. Incesu L, Coskun A, Bekir Selcuk M, Akan H, Sozubir S, Bernay F. Acute appendicitis: MR imaging and sonographic correlation. AJR Am J Roentgenol 1997; 168: 669–674.
16. Garcia Pena BM, Taylor GA. Radiologists' confidence in interpretation of sonography and CT in suspected pediatric appendicitis. AJR Am J Roentgenol 2000; 175: 71–74.
17. Sivit CJ, Applegate KE, Stallion A, et al. Imaging evaluation of suspected appendicitis in a pediatric population: effectiveness of sonography versus CT. AJR Am J Roentgenol 2000; 175:977–980.
18. Garcia-Aguayo FJ, Gil P. Sonography in acute appendicitis: diagnostic utility and influence upon management and outcome. Eur Radiol 2000; 10:1886–1893.
19. Pickuth D, Heywang-Köbrunner SH, Spielmann RP. Suspected acute appendicitis: is ultrasonography or computed tomography the preferred imaging technique? Eur J Surg 2000; 166:315–319.
20. Applegate KE, Sivit CJ, Salvator AE, et al. Effect of cross-sectional imaging on negative appendectomy and perforation rates in children. Radiology 2001; 220: 103–107.
21. Jeffrey RB Jr, Laing FC, Townsend RR. Acute appendicitis: sonographic criteria based on 250 cases. Radiology 1988; 167: 327–329.
22. Schwerk WB, Wichtrup B, Rothmund M, Rueschoff J. Ultrasonography in the diagnosis of acute appendicitis: a prospective study. Gastroenterology 1989; 97:630–639.
23. Puylaert JBCM. Acute appendicitis: US evaluation using graded compression. Radiology 1986; 158:355–360.
24. Jeffrey RB Jr, Laing FC, Lewis FR. Acute appendicitis: high-resolution real-time US findings. Radiology 1987; 163:11–14.
25. Beyer D, Rieker OR, Kaiser C, Stamm I, Horsch S. Ultrasonography in cases of suspected acute appendicitis: turning-point in diagnosis and therapy? Results of a prospective study on 669 cases. Rofo Fortschr Geb Rontgenstr Neuen Bildgeb Verfahr 1990; 152:510–515. [German]
26. Abu-Yousef MM, Bleicher JJ, Maher JW, Urdaneta LF, Franken EA Jr, Metcalf AM. High-resolution sonography of acute appendicitis. AJR Am J Roentgenol 1987; 149:53–58.
27. Ripolles T, Concepcion L, Martinez-Perez MJ, Morote Y. Appendicular involvement in perforated sigmoid disease: US and CT findings. Eur Radiol 1999; 9:697–700.
28. Puylaert JBCM, Rijke AM. An inflamed appendix at sonography when symptoms are improving: to operate or not to operate? Radiology 1997; 205:41–42.
29. Chesbrough RM, Burkhard TK, Balsara ZN, Goff WB, Davis DJ. Self-localization in US of appendicitis: an addition to graded compression. Radiology 1993; 187:349–351.
30. Patriquin HB, Garcier JM, Lafortune M, et al. Appendicitis in children and young adults: Doppler sonographic-pathologic correlation. AJR Am J Roentgenol 1996; 166:629–633.
31. Quillin SP, Siegel MJ. Diagnosis of appendiceal abscess in children with acute appendicitis: value of color Doppler sonography. AJR Am J Roentgenol 1995; 164: 1251–1254.
32. Rettenbacher T, Hollerweger A, Macheiner P, et al. Presence or absence of gas in the appendix: additional criteria to rule out or to confirm acute appendicitis—evaluation with US. Radiology 2000; 214: 183–187.
33. Rettenbacher T, Hollerweger A, Macheiner P, et al. Outer diameter of the vermiform appendix as a sign of acute appendicitis: evaluation at US. Radiology 2001; 218:757–762.
34. Braun B, Blank W. Sonographic diagnosis of acute appendicitis. Ultraschall Med 1989; 10:170–176.