Original Paper · Travail original · Originalarbeit

Ophthalmologica

Ophthalmologica 1996;210:160–162

B. G. Kremser[a]
C. Kunze[a]
J. Troger[a]
H. Ulmer[b]
G. K. Kieselbach[a]

[a] Universitätsklinik für Augenheilkunde und
[b] Institut für Biostatistik der
Universität Innsbruck, Österreich

Grid Pattern Photocoagulation for Diabetic Macular Edema – Long-Term Visual Results

Abstract

The authors reviewed the data of 226 eyes in 124 patients with clinically significant diabetic macular edema treated by grid pattern photocoagulation from 1986 to 1994 at the Ophthalmological Clinic of Innsbruck University Hospital. On the basis of baseline visual acuity (VA), eyes were classified in four groups: group 1 = VA <0.1; group 2 = VA 0.1–0.2; group 3 = VA >0.2–0.5; group 4 = VA >0.5. The development of VA from the baseline examination until the last checkup in treated eyes is reported. This classification showed a better visual outcome after photocoagulation in eyes with a decreased VA at baseline (groups 1, 2) compared with eyes with a good initial VA (groups 3, 4). The difference in visual outcome between the second and third groups as well as between the third and fourth groups was statistically significant ($p \leq 0.001$). A correlation of initial VA with visual outcome after treatment was demonstrated ($R = -0.558$; $p = 0.0001$). Clinical conclusions of these results are discussed.

Key Words

Grid pattern photocoagulation
Macular edema
Visual acuity
Diabetes mellitus

Introduction

The most frequent cause of severe visual loss in diabetic patients is diabetic macular edema [1, 2]. Several clinical trials have demonstrated that focal and grid pattern photocoagulation stabilizes visual acuity (VA) in patients with clinically significant macular edema [3–5]. Olk [6]even reported a surprisingly high rate of improvement in treated versus untreated eyes. As a result we have been performing photocoagulation in our patients according to the recommendations of the Early Treatment Diabetic Retinopathy Study (ETDRS) since 1986. In the present study, we evaluated the visual outcome of 226 eyes in 124 patients treated with focal and grid pattern photocoagulation from 1986 to 1994 at the University Eye Clinic in Innsbruck.

Patients and Methods

Eligibility criteria for the review included a diagnosis of type I or type II diabetes mellitus and clinically significant macular edema according to the ETDRS scale. The baseline examination for all patients entered in this review included: a best corrected VA using the Snellen chart; slitlamp, contact lens, direct and indirect ophthalmoscopy; fundus color photography and fluorescein angiography. With the exception of angiography, which was not performed in all patients at each ophthalmological checkup, the follow-up examination included the same investigations as the baseline examination. Scanning laser ophthalmoscopy was conducted in some cases. All patients enrolled in this study were initially examined and treated by two ophthalmologists. Exclusion criteria were the following: glycosylated hemoglobin higher than 10 mg/dl; diastolic blood pressure higher than 100 mm Hg; renal failure requiring dialysis; previous photocoagulation of the fundus; retinal detachment or schisis; history of glaucoma. All patients were treated with argon-green gridpattern photocoagulation according to ETDRS recommendations [7]. Also eyes achieving a VA better than 0.5 with retinal thickening within 200 μm of the center of the macula were included [8]. Patients with proliferative diabetic retinopathy were transferred to scatter photocoagulation after treatment of maculopathy. Follow-up examinations were performed every 4 months or

KARGER
E-Mail karger@karger.ch
Fax +41 61 306 12 34

0030–3755/96/2103–0160 $10.00/0

G.E. Kieselbach, MD
Universitätsklinik für Augenheilkunde
Anichstrasse 35
A–6020 Innsbruck (Österreich)

Received:
March 30, 1995
Accepted:
September 21, 1995

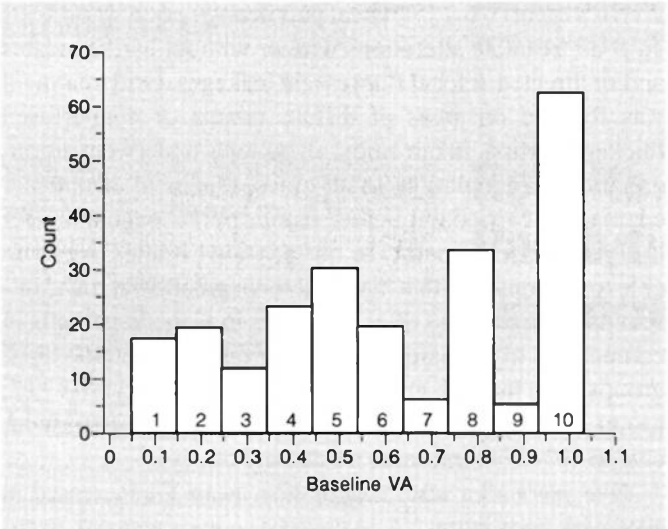

Fig. 1. Frequency distribution of VA at baseline examination in a bar chart (bars 1–10). The mean value is 0.6.

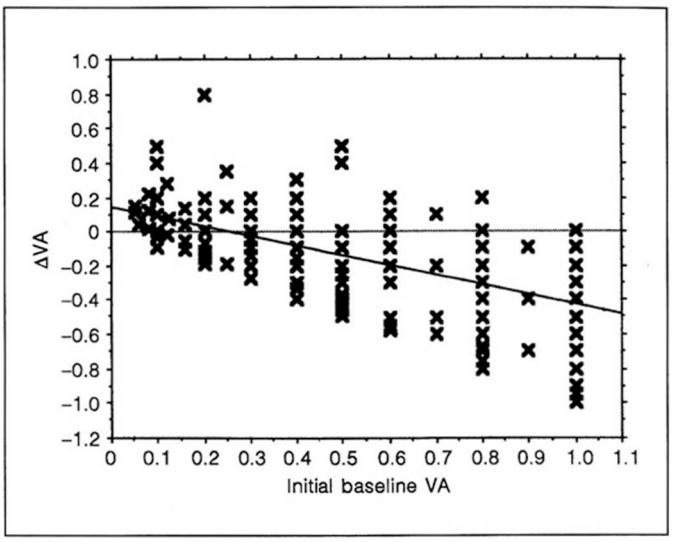

Fig. 2. Scattergram of correlation between initial VA and ΔVA (visual outcome from the first to the last examination).

Table 1. Frequency distribution of baseline VA

Bar	From	To	Count	Percent
1	0.05	0.146	17	7.522
2	0.146	0.242	19	8.407
3	0.242	0.338	12	5.31
4	0.338	0.434	23	10.177
5	0.434	0.53	30	13.274
6	0.53	0.626	19	8.407
7	0.626	0.722	6	2.655
8	0.722	0.818	33	14.602
9	0.818	0.914	5	2.212
10	0.914	1.01	62	27.434

'Bar' refers to the bars in figure 1.

earlier if necessary. For this review, baseline VA was classified in four groups: group 1 = VA <0.1; group 2 = VA 0.1–0.2; group 3 = VA >0.2–0.5; group 4 = VA >0.5. Visual outcome after photocoagulation was compared for each group using a one-factor Anova statistical test. All statistical analyses were performed on Macintosh computers with the program StatView®.

Results

The study at hand compared visual outcome after photocoagulation with initial VA in 226 eyes of 124 patients treated at our institution from 1986 to 1994. Initial VA was classified as group 1 (visus < 0.1) in 14 eyes, group 2 (visus 0.1–0.2) in 22 eyes, group 3 (visus >0.2–0.5) in 65 eyes and group 4 (visus >0.5) in 125 eyes (fig. 1, table 1). All eyes underwent argon-green photocoagulation performed by two surgeons according to ETDRS recommendations. Both eyes were treated in 102 patients (82%). The average period of time from the initial to the final examination was 5.2 years, ranging from 1 to 8 years. The patient population consisted of 57 males (46%) and 67 females (54%). The mean age was 62 years, ranging from 82 to 26 years. Of the patients, 100 (81%) suffered from type II and 24 (19%) from type I diabetes. When comparing visual results of the four groups in the period from the initial to the final examination, a statistically significant difference was seen between the second and third groups as well as between the third and fourth groups ($p \leq 0.001$; table 2). Patients with poorer initial VA (groups 1, 2) showed better visual outcome after photocoagulation as compared with patients featuring better VA at the baseline examination (groups 3, 4). The correlation of initial VA with visual outcome after treatment is shown in figure 2. Poor initial VA correlates with gratifying laser treatment results and vice versa ($R = -0.558$; $p = 0.0001$).

Discussion

Previous control studies have demonstrated that laser coagulation is effective in reducing the risk of visual loss in eyes with diabetic macular edema. In addition, some studies

Table 2. Statistical comparison of the four groups classified according to initial visus with an Anova test

A. One-factor Anova

Group	Count	Mean	SD	SE
1 (<0.1)	14	0.138	0.163	0.043
2 (0.1–0.2)	22	0.069	0.211	0.045
3 (<0.2–0.5)	65	–0.124	0.246	0.031
4 (>0.5)	125	–0.341	0.3	0.027

F = 27.346, p = 0.0001.

B. Group comparisons

Comparison	Mean difference	Fisher PLSD	Scheffe F test	Dunnett t
1 vs. 2	0.069	0.183	0.184	0.743
1 vs. 3	0.262	0.157*	3.6*	3.286
1 vs. 4	0.479	0.15*	13.101*	6.269
2 vs. 3	0.193	0.132*	2.795*	2.896
2 vs. 4	0.41	0.123*	14.271*	6.543
3 vs. 4	0.216	0.082*	9.091*	5.222

PLSD = Partial least significant difference.
*$p \leq 0.05$.

have reported on the effectiveness of gridpattern coagulation in diffuse diabetic macular edema. In 1991, Lee and Olk [9] showed the positive effect of photocoagulation in eyes with cystoid diabetic macular edema. Nevertheless, eyes with cystoid diabetic macular edema were excluded from our retrospective study based on our previous findings.

In 1986, we started treatment of diabetic macular edema as defined by the ETDRS and with indications similar to the ETDRS report No. 1 [5]. Focal photocoagulation was directed at all treatable alterations with or without hard exudates and/or directed at focal fluorescein leakages. Grid treatment was focused on areas of diffuse edema or nonperfused thickened retina. In our study, all patients underwent argon-green laser coagulation. In all cases, treatment of macular edema was carried out before scatter photocoagulation for proliferative retinopathy. In our previous studies, we were able to demonstrate that laser photocoagulation significantly reduces visual loss after 2–3 years in diabetic patients in comparison to the natural history of this disease [10]. Four groups were formed: group 1 had VA <0.1; group 2, 0.1–0.2; group 3, >0.2–0.5, and group 4 had VA >0.5. The study included 80% bilateral cases treated in both eyes.

Five years after laser coagulation mean VA increased in eyes with poor initial VA in contrast to eyes with VA better than 0.5 before treatment. We even observed a significant correlation between good visus at baseline examination and decreasing VA after photocoagulation. Eyes with an initial VA better than 0.6 deteriorated despite laser coagulation. Stabilization was seen in eyes with an initial VA between 0.2 and 0.5.

Our findings in patients with poor initial VA (between 0.1 and 0.2) urged us to explore all eyes in this group: 10 of these eyes had to be operated for cataract, while vitreous hemorrhages were managed by vitrectomy in 3 cases and both operations were required in 2 cases.

From these results we cannot conclude that photocoagulation should only be performed in eyes worse than VA <0.5. The stable course of VA in eyes with good function and the fact that VA in eyes with values >0.5 declined to 0.3–0.5 in our study population, which still enables the patient to read, confirms our former results. We therefore conclude that laser coagulation should be performed in eyes before VA decreases to 0.2.

References

1 Ferris FL III, Patz A: Macular edema. A complication of diabetic retinopathy. Surv Ophthalmol 1985;28(suppl):452–461.
2 Klein R, Moss SE, Klein BEK, Davis MD, de Mets DL: The Wisconsin Epidemiologic Study of Diabetic Retinopathy. XI. The incidence of macular edema. Ophthalmology 1989;96:1501–1510.
3 Blankenship GW: Diabetic macular edema and argon laser photocoagulation: A prospective randomized study. Ophthalmology 1979;86:69–78.
4 British Multicentre Study Group: Photocoagulation for diabetic maculopathy. Diabetes 1983;32:1010–1016.
5 Early Treatment Diabetic Retinopathy Study Research Group: Photocoagulation for diabetic macular edema. Report No 1. Arch Ophthalmol 1985;103:1796–1806.
6 Olk RJ: Modified grid argon (blue-green) laser photocoagulation for diffuse diabetic macular edema. Ophthalmology 1986;93:938–948.
7 Early Treatment Diabetic Retinopathy Study Research Group: Treatment techniques and clinical guidelines for photocoagulation of diabetic macular edema. Report No 2. Ophthalmology 1987;94:761–774.
8 Early Treatment Diabetic Retinopathy Study Research Group: Early photocoagulation for diabetic retinopathy. Report No 9. Ophthalmology 1991;98:766–785.
9 Lee CM, Olk RJ: Modified grid laser photocoagulation for diffuse diabetic macular edema: Long-term visual results. Ophthalmology 1991;98:1594–1602.
10 Kieselbach G, Juen S: Visusergebnisse bei diabetischer Makulopathie nach zentraler Photokoagulation. Ophthalmologica 1989;199:72–76.