

# Screening for Open Spina Bifida in a Routine Clinical Setting at the First-Trimester Scan: A Prospective Multicentre Cohort Study

Johanna Tiechl<sup>a</sup> Samira Abdel Azim<sup>a</sup> Katharina Leitner<sup>a</sup> Astrid Berger<sup>a</sup>  
Irene Mutz-Dehbalaie<sup>a</sup> Georg Goebel<sup>b</sup> Matthias Scheier<sup>c</sup>

<sup>a</sup>Department of Obstetrics and Gynaecology, Medical University of Innsbruck, Innsbruck, Austria; <sup>b</sup>Department of Medical Statistics, Medical University of Innsbruck, Innsbruck, Austria; <sup>c</sup>Ambulatorium für Fetalmedizin, Feldkirch, Austria

## Keywords

Open spina bifida · First-trimester screening · 11–13 weeks' scan · Brainstem/brainstem-to-occipital-bone ratio · Cisterna magna

## Abstract

**Objective:** The aim of this study was to investigate the performance of screening for open spina bifida (OSB) integrated into the routine first-trimester screening. **Method:** This is a prospective multicentre study of 4,755 women undergoing first-trimester ultrasound scans over a 4-year period. Measurements of the brainstem (BS) diameter and brainstem-to-occipital-bone (BSOB) distance were performed. The cisterna magna (CM) was measured in the tilted axial view. **Results:** Pregnancy outcome data were available for 4,658 fetuses included in this study. There were 5 fetuses with OSB, and in all of them, the BS/BSOB ratio and the CM measurements were abnormal. The sensitivity and specificity of a BS/BSOB ratio >1 were 100%. The sensitivity of a CM width <5th centile was 100%, and the specificity was 95.1%. In 4.6% of cases, the BS/BSOB ratio was between the 95th percentile and 1. In 87.1% of these cases, the CM was normal, and 12.9% had a CM below the 5th percentile. **Conclusion:** Screening

for OSB is feasible in routine first-trimester scans. The BS/BSOB ratio shows a very good sensitivity and specificity. In cases with near-normal values for the BS/BSOB ratio, the CM width might be helpful for further assessment.

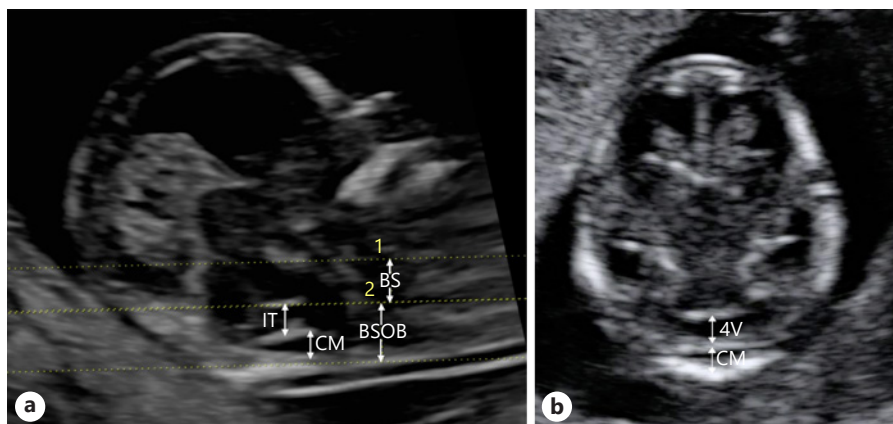
© 2021 S. Karger AG, Basel

## Introduction

Open spina bifida (OSB) affects approximately 1 in 1,000 newborns [1]. The description of the banana sign [2] caused by caudal displacement of the brainstem (BS) with consecutive obliteration of the cisterna magna (CM) has significantly improved the diagnosis of OSB at the 20-week scan. In addition to screening for chromosomal aberrations, the examination of fetal anatomy is an important part of routine first-trimester screening. A significant proportion of severe structural abnormalities can already be detected at this stage of pregnancy [3]. Early diagnosis of fetal malformations provides parents with ample time for decision-making and, for OSB in particular, counseling regarding intrauterine treatment options.

There is evidence that the development of the Chiari II malformation due to caudal displacement of the BS and

**Fig. 1.** **a** Transabdominal sonography of a fetus in a midsagittal view with a normal fossa posterior. BS, BSOB diameter, IT, the future CM, and the choroid plexus of the 4V can be easily visualized. **b** Transabdominal sonography of the fetal head in a tilted axial view, showing a normal fetus, CRL 66 mm with a normal fossa posterior. BS, brainstem; BSOB, brainstem-occipital bone; IT, intracranial translucency; CM, cisterna magna; 4V, 4th ventricle.



the obliteration of the CM as a consequence of cerebrospinal fluid leakage begins early in pregnancy, and changes are present in the fetal brain at the time of the first-trimester scan. In recent years, different screening methods for abnormalities of the fetal cerebral posterior fossa have been described [4–8]. Among the first was the observation of Lachmann et al. [7], who described, in the midsagittal view of the fetal head, the increased diameter of the BS and the reduced distance between the posterior border of the BS and the anterior border of the occipital bone (brainstem-to-occipital-bone (BSOB) distance), leading to an increased BS/BSOB ratio. Egle et al. [6] examined the fetal head in a tilted axial view and provided reference values for the fourth ventricle and the CM. The objective of this prospective study was to examine the performance of screening for OSB when integrated into the routine first-trimester assessment.

## Methods

### Patients

This is a prospective multicentre cohort study comprising 4,755 women presenting for their first-trimester assessment at the Fetal Medicine Unit of the Department of Gynecology and Obstetrics of the Medical University Hospital Innsbruck, Austria, and the Ambulatorium für Fetalmedizin, Feldkirch, Austria, between April 2011 and July 2015. Both centers offer first-trimester screening for a low-risk population but also serve as tertiary care referral units. This study was approved by the local Ethics Committee (reference number UN 4096; 292/4.12 and 293/4.2), and informed consent was obtained from all patients.

In addition to the routine first-trimester scan, in all fetuses with a crown-rump length (CRL) between 45 and 84 mm, the posterior fossa was investigated by transabdominal sonography using a Voluson E8 ultrasound machine (GE Medical Systems Kretztechnik, Zipf, Austria) equipped with a RAB 4–8-MHz probe. Measurements of the BS and BSOB distance in a midsag-

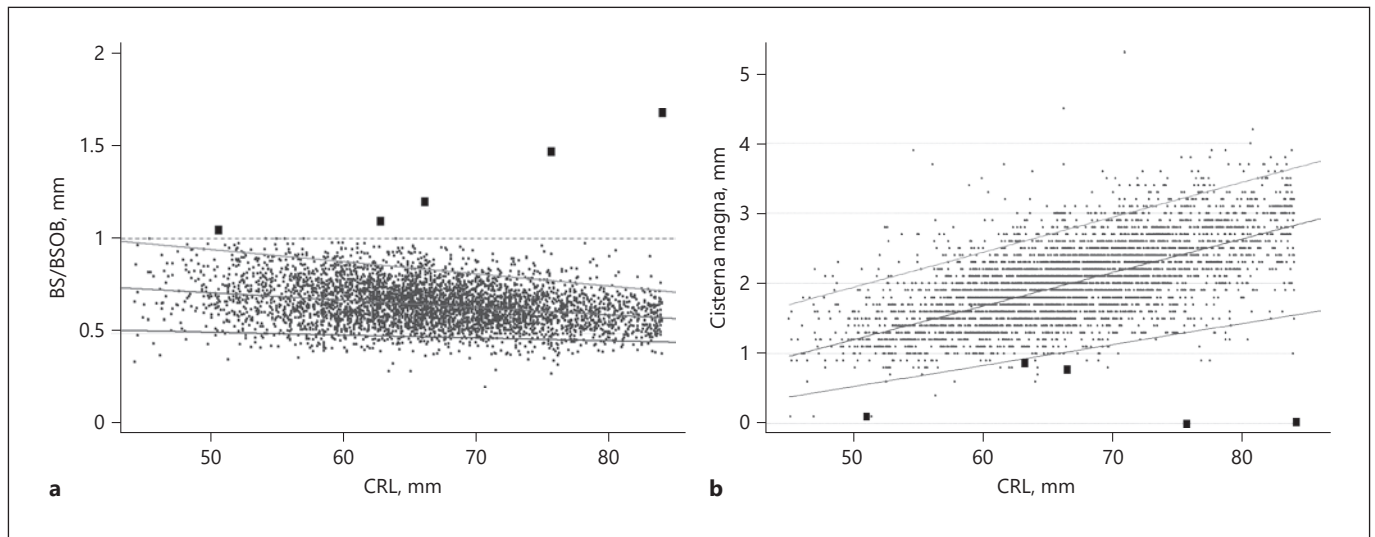
ittal view were performed as described by Lachman et al. [7]. For these measurements, the “distance 2 lines” measurement tool of the ultrasound equipment was used. The first line was set along the posterior border of the sphenoid bone, the second line along the border between the brain stem and the border of the fourth ventricle, and the third line along the anterior border of the occipital bone. The distance between the first and second line represents the BS, and the distance between the second and third line is the BSOB (Fig. 1a). The CM was measured in the tilted axial view as described by Egle et al. [6]. Both methods of the measurements of fossa posterior structures are standardized, and intra- and interobserver variability was proven to be good. Measurements in midsagittal view are shown in Figure 1a. A normal CM in the tilted axial view is depicted in Figure 1b. All scans were performed by adequately trained and FMF-certified doctors.

Hospital delivery records, detailed ultrasound examination data at the anomaly scan between 20 and 23 weeks or details from standardized phone interviews with the parents after delivery of the children, were obtained to exclude open and closed spine defects. The diagnosis of OSB was ascertained by postpartum pathological examination. Cases with missing pregnancy outcome data were excluded, including cases of miscarriage, intrauterine death, and termination of pregnancy without pathological examination of the fetus. The data of the normal population were used to construct reference values.

### Statistical Analysis

We provide frequencies and percentages for categorical variables and mean (SD) or median (IQR) for metric measurements dependent on their distribution. Spearman’s rank correlation coefficient ( $r_s$ ) was used to calculate associations between quantitative variables. Quantile regression was used to estimate median and 5/95th percentile reference ranges for the diameters of CM, BS, BSOB, and BS/BSOB diameter ratio.

Estimations of sensitivity and specificity (95% confidence intervals) are provided for the BS/BSOB ratio above 1 and for the BS/BSOB ratio above the 95th percentile. The 5th percentile of the CM diameter was investigated as an additional potential diagnostic threshold. The statistical software packages SPSS 24.0 (SPSS, Chicago, IL, USA) and STATA 14 (StataCorp, College Station, TX, USA) were used for data analyses.



**Fig. 2.** **a** Measurements of the ratio between the BS diameter and BSOB diameter in fetuses with OSB (big squares) and normal controls (small squares). **b** Measurements of the CM width in the tilted axial view plotted on the reference range for CRL in fetuses with OSB (big squares) and normal controls (small squares). BS, brainstem; BSOB, brainstem-occipital-bone; CRL, crown-rump length; CM, cisterna magna.

## Results

Of the 4,949 fetuses included in this study, 4,658 had available pregnancy outcome data. There were 328 twin (7%) and 30-triplet (0.6%) pregnancies. Of the 291 (5.9%) fetuses without pregnancy outcome data, 71% were lost to follow-up, 12% ended in a miscarriage or intrauterine death, and 17% ended in termination of pregnancy due to chromosomal anomalies, fetal abnormalities other than OSB, or unknown reasons. There were 5 cases of OSB giving an incidence of 1.07 in 1,000 pregnancies in our study population. The mean CRL was 66.7 mm (SD 7.94). The mean maternal age was 32.7 years (SD 5.28). The demographic data and ultrasound data of our study population are shown in Table 1.

BS, BSOB, and CM width correlated significantly with CRL and increased with gestational age: CM ( $r_s = 0.63$ ), BS ( $r_s = 0.49$ ), and BSOB ( $r_s = 0.77$ ). The BS/BSOB ratio slightly decreased with advancing gestation ( $r_s = 0.27$ ). The relation between CRL and BS/BSOB and CM are depicted in Figure 2a and b, respectively. The CRL length was used as regression predictor in the quantile regression model. There was an increase with CRL in BS ( $0.853 + 0.0361 \times \text{CRL}$  in mm,  $R^2 = 0.14$ ) and BSOB diameter ( $-0.66 + 0.086 \times \text{CRL}$  in mm,  $R^2 = 0.38$ ). The median BS/BSOB ratio decreased with CRL ( $0.91 - 0.004 \times \text{CRL}$ ,  $R^2 = 0.04$ ; Fig. 2a), whereas the median diameter of CM in-

**Table 1.** Characteristics of study population

Values	Mean	SD
Maternal age, years	32.7	5.28
BMI	23.7	4.79
CRL, mm	66.73	7.94
NT, mm	1.98	0.58
BS, mm	3.27	0.55
BSOB, mm	5.01	0.89
CM, mm	2.03	0.57

CRL, crown-rump length; NT, nuchal translucency; BS, brainstem; BSOB, brainstem-occipital bone; CM, cisterna magna; SD, standard deviation.

creased with CRL ( $-1.21 + 0.05 \times \text{CRL}$ ,  $R^2 = 0.23$ ; Fig. 2b). The reference ranges for BS/BSOB and CM ratio are depicted in Table 2.

This series included 5 cases of OSB (Fig. 3) and 2 cases of spina bifida occulta. All cases with OSB were detected in the first trimester. Cases with spina bifida occulta showed normal values for CM, BS, BSOB, and the BS/BSOB ratio and were detected only on the second-trimester anomaly scan.

The detection rate for all cases of OSB with a BS/BSOB ratio  $>1$  was 100%, with a false-positive rate of 0% (95%

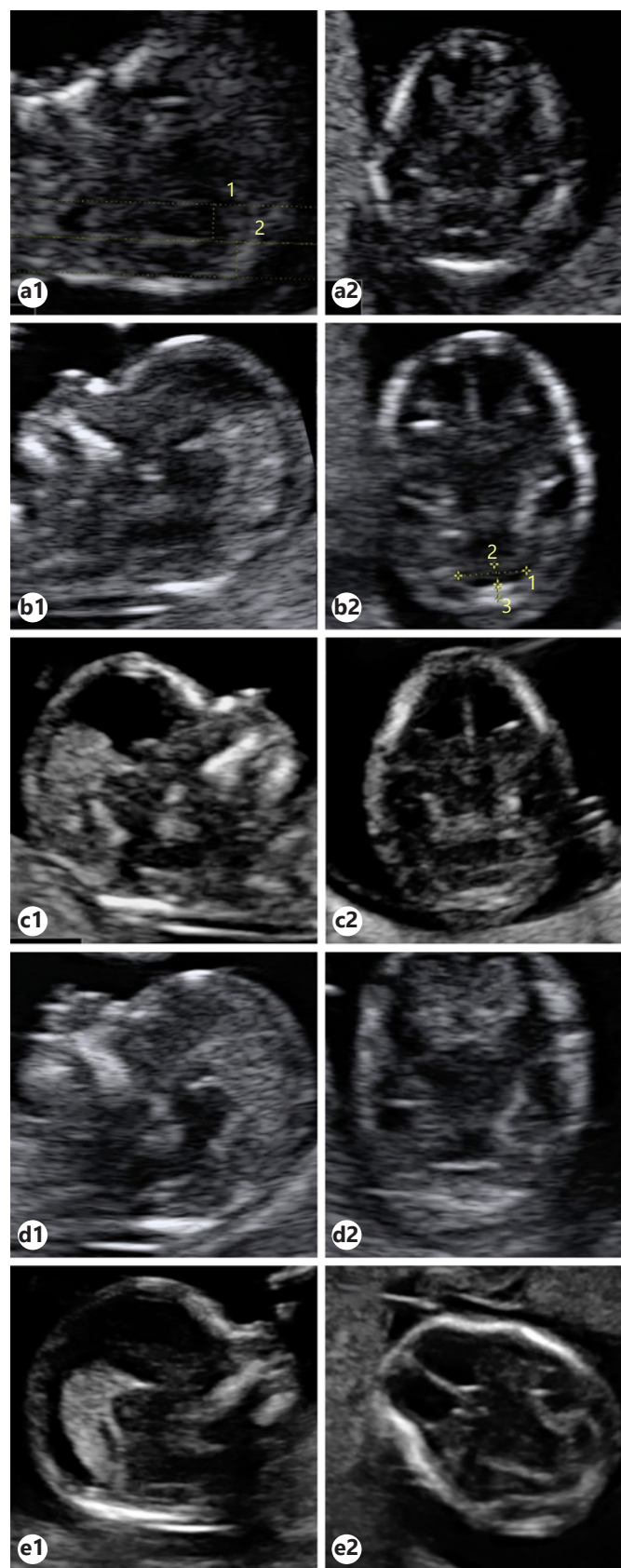
CI, 99.9–100). When the 95th percentile of the BS/BSOB ratio was used, the detection rate for OSB remained the same (100%) but the false-positive rate was 4.7% (95% CI, 94.6–95.9). A CM measurement below the 5th percentile showed a detection rate for OSB of 100%, with a false-positive rate of 4.9% (95% CI, 94.4–95.7). In all cases with OSB, the CM measurements were below the 5th percentile as shown in Figure 2b. In 4.6% of cases, the BS/BSOB ratio was between the 95th percentile and the arbitrary cutoff of 1. In these cases, 87.1% had a normal CM width.

## Discussion

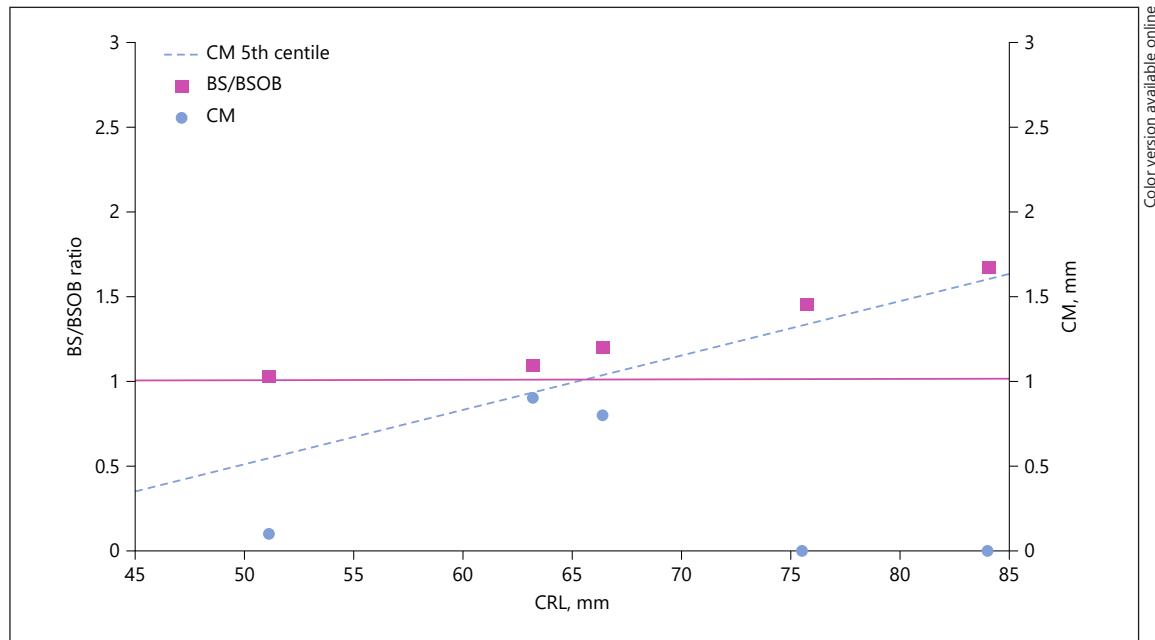
This prospective study demonstrates the excellent performance of the BS/BSOB ratio for OSB screening when incorporated into the first-trimester assessment in a routine clinical setting, with a sensitivity and specificity of 100%. CM measurements below the 5th centile also show a 100% sensitivity but at a false-positive rate of 4.9%. BS/BSOB ratio above 1 performs better regarding specificity. However, for cases with a BS/BSOB ratio close to 1, the addition of the measurement of CM might ease the diagnosis of a fossa posterior malformation, as the extent of deviation from normal might not be equally pronounced in both measurements as shown in Figure 4. The addition of CM measurements further helps to exclude 87% of the falsely positive identified fetuses by an increased BS/BSOB ratio above the 95th percentile.

In cases with OSB, the BS is displaced caudally and dorsally causing eventually an increase in the diameter of the BS measurements and an obliteration of the fourth ventricle and the CM. These changes are the anatomical basis of the different ultrasound markers observed in fetuses with OSB in the first trimester. Latest research on fetuses with OSB has shown an increase in the incidence of Chiari II malformations from 31% before 16 weeks to 91.6% after 16 weeks. In the exposed cord, significant neural loss is present already before 16 gestational weeks and extends progressively over time [9]. Fietz et al. [10] demonstrated impaired neocortical development in fetuses with OSB and cell cycle changes in neuronal progenitor cells leading

**Fig. 3.** Median sagittal section (1) and tilted axial view (2) of the posterior fossa in fetuses with OSB. **a** CRL 51 mm, BS/BSOB 1.04; CM 0.1 mm. **b** CRL 63 mm, BS/BSOB 1.09; CM 0.9 mm. **c** CRL 66 mm, BS/BSOB 1.20; CM 0.8 mm. **d** CRL 76 mm, BS/BSOB 1.46; CM obliterated. **e** CRL 84 mm, BS/BSOB 1.31; CM obliterated. BS, brainstem; BSOB, brainstem-occipital-bone; CRL, crown-rump length; OSB, open spina bifida.



Color version available online



Color version available online

**Fig. 4.** All 5 cases of OSB plotted with their respective BS/BSOB ratio (purple squares) and CM measurements (blue dots). All OSB cases have a BS/BSOB ratio above 1 (purple line) and a CM below the 5th centile (dashed blue line). BS, brainstem; BSOB, brainstem-occipital-bone.

**Table 2.** Reference values (95% CIs) of BS/BSOB ratio and CM based on measurements in healthy fetuses at 11–14 weeks' gestation according to CRL categories

	<i>n</i>	5th percentile	50th percentile	95% percentile
<i>BS/BSOB ratio</i>				
<i>CRL, mm</i>				
45–54	289	0.49 (0.44–0.51)	0.69 (0.68–0.72)	0.94 (0.90–0.95)
55–64	1,460	0.49 (0.48–0.50)	0.68 (0.67–0.68)	0.88 (0.86–0.90)
65–74	1,986	0.48 (0.47–0.50)	0.64 (0.63–0.66)	0.83 (0.81–0.84)
75–84	788	0.45 (0.44–0.46)	0.60 (0.59–0.61)	0.77 (0.75–0.80)
<i>CM width, mm</i>				
<i>CRL, mm</i>				
45–54	278	0.9 (0.8–0.91)	1.3 (1.2–1.4)	2.1 (2.0–2.2)
55–64	1,411	1.1 (1.02–1.1)	1.7 (1.69–1.71)	2.5 (2.4–2.6)
65–74	1,889	1.4 (1.39–1.41)	2.1 (2.09–2.11)	2.9 (2.89–3.0)
75–84	719	1.6 (1.5–1.8)	2.6 (2.59–2.7)	3.5 (3.4–3.6)

95% confidence intervals of the reference values were calculated based on 1,000 bootstrap replications. CRL, crown-rump length; BS/BSOB, brainstem-to-brainstem occipital bone; CM, cisterna magna.

to a marked reduction in radial neocortical thickness. These findings emphasize the importance of early diagnosis for potential early fetal intervention.

In recent years, many studies have investigated the performance of different markers in the detection of OSB in the first trimester. Chaoui et al. [4] published reference

ranges of the fourth-ventricle anteroposterior diameter according to CLR in 200 normal fetuses. For this structure, they coined the term intracranial translucency (IT). In another 4 fetuses affected by spina bifida, there was a complete obliteration of the IT. Lachmann et al. [7] found in fetuses with OSB an increased BS diameter and a de-

creased BSOB distance due to caudal displacement of the BS and compression of the fourth ventricle. This study described the accurate technique for measurement of the BS diameter and the brainstem-to-occipital-bone diameter in a midsagittal section. The ratio between these parameters named BS/BSOB was found to be above 1 in all 30 fetuses with OSB [7]. In the same year, Chaoui et al. [11] published a series of 6 cases of OSB, wherein they found an increased BS/BSOB ratio of  $\geq 1$  in all cases, an obliterated IT in only 2 of the 6 cases but a reduced amount of fluid in the other 4 cases. Solt et al. [12] conducted a retrospective study on stored first-trimester images to examine the efficacy of nonvisualization of the IT in fetuses with spina bifida. They found a detection rate of only 45% for nonvisualization of IT in cases with spina bifida [12]. Likewise, the retrospective study by Mangione found that nonvisualization of IT was associated with a relatively low detection rate for all observers and only moderate agreement between specialists [13]. Karl et al. [14] measured the posterior fossa fluid area, which is the sum of the fluid area of the IT and of the fluid area of the CM. In 21 fetuses with OSB, they found a decreased posterior fossa fluid area as compared to 220 normal fetuses. Kappou et al. [15] measured the IT in a prospective study of 2,491 fetuses, including 3 cases with OSB and established an IT to CM ratio. This ratio was abnormal in 2 of 3 cases with OSB. Chen et al. [16] conducted a prospective study in 15,526 fetuses, examined by highly experienced experts. All 11 cases of OSB were detected with a combination of different markers. There was no single marker with a 100% sensitivity. The detection rates for absence of IT, IT below the first centile, obliteration of the CM, CM below the first centile, and BS/BSOB ratio above the 99th centile were 18, 45, 64, 73, and 36%, respectively [16]. In a retrospective case-control study including 27 fetuses with spina bifida, Wertaschnigg et al. [17] assessed the IT, BS/BSOB, and maxillo-occipital line in the sagittal view. They reported a detection rate for IT below the fifth percentile, BS/BSOB above the 95th percentile, and an abnormal maxillo-occipital line of 52.3, 96.3, and 96.3%, respectively. Maruotti et al. [18] who evaluated the performance of the IT in the detection of OSB in a meta-analysis found a similar detection rate of 53.5% for an IT measurement below the cutoff defined by the original studies.

In a prospective study that included 1,479 fetuses, Kose et al. [19] showed a BS/BSOB ratio above the 95th percentile and nonvisualization of the CM in 2 fetuses affected by OSB. Scheier et al. [8] prospectively investigated the posterior fossa in stored 3D volumes in 10 normal fetuses and 3 fetuses with OSB and found an increased

BS/BSOB ratio and a partial or complete obliteration of the CM in all cases of OSB. These findings are in line with our results showing an increased BS/BSOB ratio (above 1) in all cases of OSB but in none of the healthy fetuses.

The feasibility in depicting the CM was demonstrated by Egle et al. [6] who constructed reference ranges of the CM width in 604 healthy fetuses in a tilted axial view. These reference ranges fit well to the curves established by Garcia-Posada et al. [20] in 80 healthy fetuses in a midsagittal plane. The latter found a CM below the 5th percentile and a BS/BSOB ratio above the 95th centile in all 5 fetuses with OSB. In a study of 1,330 fetuses, Kavalakis et al. [21] showed an obliterated CM in one of only 2 fetuses with OSB in a midsagittal view. In our cohort, we assessed the CM only in the tilted axial view and found that it was below the 5th percentile in all OSB cases and completely obliterated in 2 of these fetuses.

To the best of our knowledge, this is the first prospective study to demonstrate the performance of the measurement of the BS/BSOB ratio in a routine clinical setting in a low-risk population. In one other large prospectively designed study, all measurements in the posterior fossa were assessed including IT, CM, BS, BSOB, and BS/BSOB. Although the reported detection rate of OSB was 100%, all of them could only be confirmed after 2 ultrasound scans by a combination of the abovementioned measurements [16].

Due to the rarity of the disease, the numbers of affected fetuses by OSB are still low. However, the excellent sensitivity and specificity are promising even with relatively small numbers of cases. We believe that we can demonstrate a satisfying feasibility of screening.

## Conclusion

Prerequisites for screening in clinical practice are easy-to-obtain measurements with sufficient reproducibility, clear cutoff values, and a reasonable sensitivity and specificity of the test. For these reasons and because these measurements can be taken in the same midsagittal view used for the measurement of the nuchal translucency, we studied the performance of the BS/BSOB ratio [5]. However, similar to the examination of other malformations, additional planes are applied in cases of suspicious findings. Therefore, we incorporated the measurement of the CM in the tilted axial view. We hypothesize that particularly in cases with slight elevation of the BS/BSOB ratio the assessment of the CM in the tilted axial view might contribute to the accuracy of the test. We conclude that screening for

OSB is feasible in routine first-trimester scans. The BS/BSOB ratio shows excellent sensitivity and specificity. In cases with near-normal values for the BS/BSOB ratio, the CM width might be helpful for further assessment.

### Statement of Ethics

Ethics approval was obtained from the Ethics Committee of Medical University of Innsbruck, Austria (reference number UN 4096; 292/4.12 and 293/4.2) and has been performed in accordance with the ethical standards laid down in the 1964 Declaration of Helsinki and its later amendments. Informed written consent was obtained from each woman included in this study.

### Conflict of Interest Statement

The authors have no conflicts of interest to declare.

### References

- 1 Khoshnood B, Loane M, de Walle H, Arriola L, Addor MC, Barisic I, et al. Long term trends in prevalence of neural tube defects in Europe: population based study. *BMJ*. 2015 Nov 24; 351:h5949.
- 2 Nicolaides KH, Campbell S, Gabbe SG, Guidetti R. Ultrasound screening for spina bifida: cranial and cerebellar signs. *Lancet*. 1986 Jul 12;2(8498):72–4.
- 3 Syngelaki A, Hammami A, Bower S, Zidere V, Akolekar R, Nicolaides KH. Diagnosis of fetal non-chromosomal abnormalities on routine ultrasound examination at 11–13 weeks' gestation. *Ultrasound Obstet Gynecol*. 2019 Oct; 54(4):468–76.
- 4 Chaoui R, Benoit B, Mitkowska-Wozniak H, Heling KS, Nicolaides KH. Assessment of intracranial translucency (IT) in the detection of spina bifida at the 11–13-week scan. *Ultrasound Obstet Gynecol*. 2009 Sep;34(3):249–52.
- 5 Chaoui R, Nicolaides KH. Detecting open spina bifida at the 11–13-week scan by assessing intracranial translucency and the posterior brain region: mid-sagittal or axial plane? *Ultrasound Obstet Gynecol*. 2011 Dec;38(6): 609–12.
- 6 Egle D, Strobl I, Weiskopf-Schwendinger V, Grubinger E, Kraxner F, Mutz-Dehbalaie IS, et al. Appearance of the fetal posterior fossa at 11 + 3 to 13 + 6 gestational weeks on transabdominal ultrasound examination. *Ultrasound Obstet Gynecol*. 2011 Dec;38(6):620–4.
- 7 Lachmann R, Chaoui R, Moratalla J, Picciarelli G, Nicolaides KH. Posterior brain in fetuses with open spina bifida at 11 to 13 weeks. In: Chitty LS, Lau TK, editors. *Prenatal Diagnosis*. Vol. 31. John Wiley & Sons, Ltd.; 2011. p. 103–6.
- 8 Scheier M, Lachmann R, Pětroš M, Nicolaides KH. Three-dimensional sonography of the posterior fossa in fetuses with open spina bifida at 11–13 weeks' gestation. *Ultrasound Obstet Gynecol*. 2011 Dec;38(6):625–9.
- 9 Ben Miled S, Loeuillet L, Duong Van Huyen JP, Bessières B, Sekour A, Leroy B, et al. Severe and progressive neuronal loss in myelomeningocele begins before 16 weeks of pregnancy. *Am J Obstet Gynecol*. 2020 Aug;223(2):256–e9.
- 10 Fietz SA, Namba T, Kirsten H, Huttner WB, Lachmann R. Signs of reduced basal progenitor levels and cortical neurogenesis in human fetuses with open spina bifida at 11–15 weeks of gestation. *J Neurosci*. 2020 Feb 19;40(8): 1766–77.
- 11 Chaoui R, Benoit B, Heling KS, Kagan KO, Pietzsch V, Sarut Lopez A, et al. Prospective detection of open spina bifida at 11–13 weeks by assessing intracranial translucency and posterior brain. *Ultrasound Obstet Gynecol*. 2011 Dec;38(6):722–6.
- 12 Solt I, Acuna JG, Adeniji BA, Mirocha J, Kim MJ, Rotmensch S. First-trimester visualization of the fourth ventricle in fetuses with and without spina bifida. *J Ultrasound Med*. 2011; 30(12):1643.
- 13 Mangione R, Dhombres F, Lelong N, Amat S, Atoub F, Friszer S, et al. Screening for fetal spina bifida at the 11–13-week scan using three anatomical features of the posterior brain. *Ultrasound Obstet Gynecol*. 2013 Oct; 42(4):416–20.
- 14 Karl K, Heling KS, Chaoui R. Fluid area measurements in the posterior fossa at 11–13 weeks in normal fetuses and fetuses with open spina bifida. *Fetal Diagn Ther*. 2015 Feb 10; 37(4):289–93.
- 15 Kappou D, Papastefanou I, Pilalis A, Kavalkis I, Kassanos D, Souka AP. Towards detecting open spina bifida in the first trimester: the examination of the posterior brain. *Fetal Diagn Ther*. 2015 Feb 18;37(4):294–300.
- 16 Chen FC, Gerhardt J, Entezami M, Chaoui R, Henrich W. Detection of spina bifida by first trimester screening: results of the prospective multicenter berlin IT-study. *Ultraschall Med*. 2015 Apr 14;38(2):151–7.
- 17 Wertaschnigg D, Ramkrishna J, Ganesan S, Tse C, Scheier M, Volpe N, et al. Cranial sonographic markers of fetal open spina bifida at 11 to 13 weeks of gestation. *Prenatal Diagnosis*. 2020 Feb;40(3):365–72.
- 18 Maruotti GM, Saccone G, D'Antonio F, Berghella V, Sarno L, Morlando M, et al. Diagnostic accuracy of intracranial translucency in detecting spina bifida: a systematic review and meta-analysis. *Prenat Diagn*. 2016; 36(11):991–6.
- 19 Kose S, Altunyurt S, Keskinoglu P. A prospective study on fetal posterior cranial fossa assessment for early detection of open spina bifida at 11–13 weeks. *Congenit Anom*. 2017 Apr 5;58(1):4–9.
- 20 Garcia-Posada R, Eixarch E, Sanz M, Puerto B, Figueras F, Borrell A. Cisterna magna width at 11–13 weeks in the detection of posterior fossa anomalies. *Ultrasound Obstet Gynecol*. 2013 May;41(5):515–20.
- 21 Kavalkis I, Souka AP, Pilalis A, Papastefanou I, Kassanos D. Assessment of the posterior brain at 11–14 weeks for the prediction of open neural tube defects. *Prenat Diagn*. 2012 Oct 4;32(12):1143–6.

### Funding Sources

This research did not receive any specific grant from funding agencies in the public, commercial, or not-for-profit sectors. Resources were generously provided by the Department of Obstetrics and Gynaecology, Medical University of Innsbruck, Austria, and the Ambulatorium für Fetalmedizin Feldkirch, Austria.

### Author Contributions

J. Tiechl: data collection and manuscript writing. S. Abdel Azim: data analysis and manuscript writing. K. Leitner: data analysis. A. Berger: data collection. I. Mutz-Dehbalaie: data collection and manuscript editing. G. Goebel: statistical data analysis. M. Scheier: data collection, project development, and critical revision.