The Volume of Ischemic Brain Predicts Poor Outcome in Patients with Surgically Treated Malignant Stroke

Christian F. Freyschlag[1], Christian Boehme[2], Marlies Bauer[1], Johannes Kerschbaumer[1], Daniel Pinggera[1], Marina Riedmann[3], Claudia Unterhofer[1], Astrid E. Grams[4], Michael Knoflach[2], Claudius Thomé[1]

■ BACKGROUND: **Malignant middle cerebral artery stroke is a life-threatening condition. The outcomes of surgical treatments have presented strong evidence in favor of decompressive hemicraniectomy (DHC). A significant subpopulation of patients still experience very poor outcomes. In particular, indication for DHC is based on few objective parameters to facilitate decision making. We hypothesized that larger ischemic brain volume would have a large impact on the outcome.**

■ METHODS: **A cohort study of 34 patients undergoing DHC was performed using a volumetric analysis of infarction volume (measured preoperatively and again on postoperative day [POD] 1 and POD 3). Outcomes were assessed using the modified Rankin Scale (mRS), and a favorable outcome was defined as modified Rankin Scale score ≤3.**

■ RESULTS: **Median age of patients was 53.5 years (range, 25–72 years), the median time from onset of first symptoms to surgical intervention was 38 hours (range, 10–150 hours), and male-to-female ratio was 2:1. The median ischemic volume was 250 cm^3 preoperatively, 315 cm^3 on POD1, and 349 cm^3 on POD3. Modified Rankin Scale score ≤3 after 6 months was attained in 7 (20%) patients. Within the first 24 hours after DHC, ischemic volume increased significantly ($P = 0.0003$) and was associated with a worse outcome ($P < 0.0001$) after exceeding a cutoff volume of 300 cm^3.**

■ CONCLUSIONS: **Volumetric analysis of infarction can predict the outcome of patients. DHC should be reserved for patients with prognosticated good outcome, which was observed only in patients with a volume <301 cm^3.**

INTRODUCTION

According to the World Health Organization, approximately 15 million strokes occur worldwide per year,[1] with one third of patients rendered severely disabled and another third dying of stroke or related sequelae. The treatment of stroke has greatly improved in recent years, with endovascular and medical treatments leading to favorable results.[2] The surgical treatment of middle cerebral artery (MCA) stroke consists of decompressive hemicraniectomy (DHC) in cases termed malignant MCA infarction, defined by the development of significant edema and consequent intracranial hypertension. The indications for and results of DHC have been studied in well-designed randomized controlled trials.[3-5] DHC has been shown to have a significant impact on patients' survival and neurologic outcome. The DESTINY trial was discontinued owing to superiority of the treatment group. The investigators in that trial found a number needed to treat of 2 in terms of survival, and a number needed to treat of 4 in terms of favorable neurologic outcome, which was defined as a modified Rankin Scale (mRS) score <4 (independently mobile).[6]

Although the usefulness of DHC from an individual patient perspective is still debated, the data with respect to survival and functional outcome are unambiguous. The quality of life after DHC has been assessed in patients who experienced favorable outcomes, and although impaired quality of life, mainly in terms

Key words
- Computed tomography
- Decompressive hemicraniectomy
- Outcome
- Stroke
- Volumetry

Abbreviations and Acronyms
CT: Computed tomography
DHC: Decompressive hemicraniectomy
MCA: Middle cerebral artery
mRS: Modified Rankin Scale
POD: Postoperative day

From the Departments of [1]Neurosurgery, [2]Neurology, [3]Medical Statistics, Informatics and Health Economics, and [4]Neuroradiology, Medical University of Innsbruck, Innsbruck, Austria

To whom correspondence should be addressed: Christian F. Freyschlag, M.D. [E-mail: christian.freyschlag@i-med.ac.at]

Citation: World Neurosurg. (2019) 123:e515-e519.
https://doi.org/10.1016/j.wneu.2018.11.197

*Journal homepage: **www.journals.elsevier.com/world-neurosurgery***

*Available online: **www.sciencedirect.com***

of physical domains, has been reported, most patients (and caregivers) were satisfied with the treatment.[7] It has been shown that volume of ischemic tissue >100 cm^3 on magnetic resonance imaging correlates with the risk of hemorrhagic transformation and poorer outcomes.[8] The ischemic tissue volume itself, to our knowledge, has not been assessed with respect to predicting patient outcomes.

We hypothesized that the outcome of patients with larger volumes of ischemic tissue would be worse. Therefore, we assessed the volume of infarction on regular computed tomography (CT) scans and correlated this with the outcome of patients who underwent DHC. Our intention was to distinguish between patients who benefited greatly from DHC and patients who experienced poorer outcomes. We additionally aimed at identifying a cutoff value that would delineate bad from good outcomes.

MATERIALS AND METHODS

All ischemic strokes are included in a prospective local stroke database and covered within the Austrian Stroke Unit Registry.[9] This database has been approved by the institutional review board. The data presented in this article were obtained in a clinical context, and the treatment protocol described reflects our standard clinical approach. Every year >1000 patients with all types of ischemic stroke are admitted to the Department of Neurology. The prospective database was filtered to identify patients who underwent DHC for ischemic MCA infarction. Of 5728 patients presenting with any type of ischemic stroke between January 2009 and December 2014, 34 patients with a diagnosis of malignant MCA infarction who underwent DHC for clinical signs of deterioration were identified. All patients included met the following criteria: a minimum follow-up of 6 months, complete CT imaging available, and no signs of intracerebral hemorrhage before surgical decompression. Patients who received intravenous thrombolysis were also included. No patient in this cohort received interventional thrombectomy. The mRS score at 6 months was defined as the primary outcome parameter; an mRS score ≤3 was considered to be a favorable outcome. Other parameters evaluated in relation to the outcome were the volume of ischemic brain tissue on CT preoperatively, on postoperative day (POD) 1, and on POD 3; the size of the craniectomy; and the National Institutes of Health Stroke Scale score. Clinical examinations during the follow-up period were performed by an independent neurologist (M.K.) before our retrospective evaluation. A bony decompression of >12 cm was mandated in several studies. We measured craniectomy size as the straight line including the largest fronto-occipital diameter of the bony defect as seen on postoperative axial CT.

Volumetric analysis was performed with OsiriX DICOM Workstation Version 4.1 32-bit freeware (Pixmeo SARL, Bernex, Switzerland) using manual segmentation of the hypodense ischemic brain on CT scans. All measurements were performed by 1 investigator (C.B.) blinded for the outcome. The statistical analysis was performed using IBM SPSS Version 21 software (IBM Corporation, Armonk, New York, USA) and Prism Version 7.0b software (Graphpad Software Inc., STATCON GmbH, Witzenhausen, Germany). Normality of data was determined using the Kolmogorov-Smirnov test, differences in volumes were examined with the help of paired-samples t test or Wilcoxon test, as appropriate. For determination of the cutoff value of ischemic tissue volume, a receiver operating characteristic curve analysis was computed.

RESULTS

Of 34 included patients, 23 were men and 11 were women, resulting in a male-to-female ratio of 2:1. The median age was 53.5 years (range, 25–72 years). There were 22 right-sided (65%) and 12 left-sided (35%) strokes. Involved territories were as follows: MCA only in 22 patients (65%); MCA and anterior cerebral artery in 7 patients (21%); MCA and posterior cerebral artery in 2 patients (6%); and MCA, anterior cerebral artery, and posterior cerebral artery in 3 cases (9%) (Table 1).

All patients were asymptomatic before stroke. The median time from the onset of symptoms to surgical intervention was 38.2 hours (range, 10–150 hours). In 21 patients (62%), surgical decompression was performed within the first 48 hours after presentation. The median National Institutes of Health Stroke Scale score at presentation was 17 (range, 6–36) with deterioration to median National Institutes of Health Stroke Scale score at discharge of 22 (range, 14–36). All but 4 patients (88%) were admitted with clinical signs of stroke but no demarcation of ischemic tissue on the initial CT scan.

Volumetric analysis of ischemic tissue detected a median preoperative volume of 250 cm^3 (range, 106–418 cm^3), increasing after surgical decompression to a median volume of 315 cm^3 (range, 141–505 cm^3; $P = 0.0003$). Further increases in volume were noticed on POD 3, with a median volume of 349 cm^3 (range, 177–617 cm^3; P = not significant) (Figure 1). The median size of the craniectomy was 12.8 cm (range, 10.4–14.7 cm) as observed on postoperative CT scans.

The mRS score at 6 months, the primary outcome parameter, was ≤3 in 5 patients (15%) and >3 in 29 patients (85%); 8 patients (23.5%) died before reaching the 6-month postoperative follow-up period (mRS score = 6). After 6 months, the mRS score improved in 2 patients, resulting in 7 patients (21%) with mRS score ≤3 and 27 patients (79%) with mRS score >3. However, 15 patients (44%) were dead at 6-month follow-up (Figure 2).

A statistical analysis of the relationship between outcome and volume of ischemic brain tissue showed a highly significant correlation ($P < 0.0001$) (Figure 3), whereas the size of the craniectomy showed no additional influence on favorable outcome (mRS score ≤3; $P = 0.826$) (Figure 4). A cutoff value for preoperative volume of infarction associated with poor outcomes (mRS score = 4–6) was computed using a receiver operating characteristic curve analysis (area = 0.950, SE = 0.048) for >300 cm^3, with a sensitivity of 100% (95% confidence interval, 0.856–1.000) and specificity of 65.2%. No patients with a preoperative ischemic tissue volume >300 cm^3 (Figure 5) achieved good outcomes at 6 months.

DISCUSSION

Our results support the hypothesis that larger volumes of ischemic tissue result in worse outcomes and that DHC may need to be

Table 1. Demographic Information, Distribution of Territories, and Outcomes

Variable	Value
Age, years, median (range)	53.5 (25–75)
Sex, number	
Female	23
Male	11
Side, number (%)	
Left	12 (35)
Right	22 (65)
Time to surgery, hours, median (range)	38.2 (0–150)
Volume, cm^3, median (range)	
Preoperative	250 (106–418)
POD 1	315 (141–505)
POD 3	349 (177–617)
Territories, number (%)	
MCA	22 (65)
MCA + ACA	7 (21)
MCA + PCA	2 (6)
MCA + ACA + PCA	3 (9)
NIHSS score, median (range)	
Admission	17 (6–36)
Dismissal	22 (14–36)
3-month outcome, number (%)	
mRS score ≤3	5 (15)
mRS score >3	29 (85)
6-month outcome, number (%)	
mRS score ≤3	7 (21)
mRS score >3	27 (89)

POD, postoperative day; MCA, middle cerebral artery; ACA, anterior cerebral artery; PCA, posterior cerebral artery; NIHSS, National Institutes of Health Stroke Scale; mRS, Modified Rankin scale.

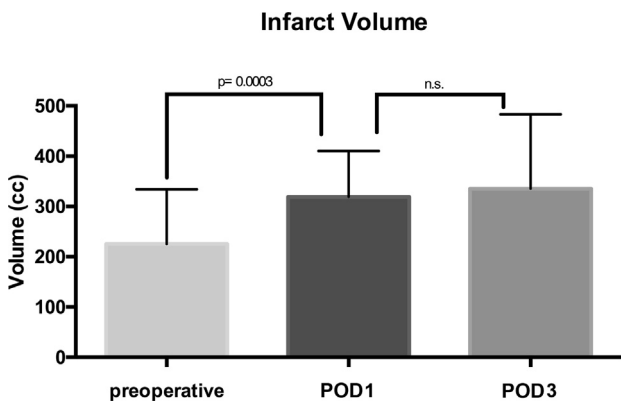

Figure 1. Volumes of ischemic brain preoperatively and on postoperative days 1 and 3. The difference between preoperative and postoperative day 1 was statistically significant ($P = 0.0003$). Statistical significance was not reached between postoperative day 1 and postoperative day 3 (mean ± SD). n.s., not significant; POD, postoperative day.

performed based on carefully determining the indications for surgery in cases of extensive strokes. To our knowledge, the present study is the first cohort analysis of surgically treated malignant MCA stroke with emphasis on the volume of ischemic brain tissue. Recent randomized controlled trials on malignant MCA stroke have demonstrated that patients benefit greatly from surgery if it is performed immediately when signs of clinical deterioration are noted.[3,10] Our study assessed objective imaging criteria of patients who underwent DHC after MCA stroke.

In our cohort, 62% of patients underwent DHC within 48 hours after admission. The DESTINY[3] and DECIMAL[4] trials reported a median time to DHC of 24 hours and 20 hours, respectively. Although the inclusion criteria of both randomized controlled trials mandated a demarcation of at least two thirds of the MCA territory, 24% of our cohort showed no signs of demarcation on CT at admission, but all patients showed demarcation before surgical intervention. Our analysis demonstrated a 6-month mortality rate (mRS score = 6) of 23.5%, which was consistent with the published literature (DESTINY, 18%; DECIMAL, 25%).[3-5] Nonetheless, 67.7% of patients had an mRS score >3 after 6 months.

We analyzed imaging preoperatively, postoperatively (within 24 hours), and on POD 3. Preoperative volume showed a significant impact on the outcome. In our results, the size of the DHC bone flap did not have a statistically significant influence on the patients' outcome. The median size of DHC was 12.8 cm, which was considered adequate for decompression in earlier trials.[3-5]

The analysis of volumes showed a significant correlation between higher volumes and poorer outcomes. The receiver operating characteristic curve analysis revealed a cutoff value of >300 cm^3 preoperatively, with high sensitivity. Magnetic resonance imaging studies of ischemic tissue volumes indicated a lower cutoff value of 105 cm^3,[11] which correlated with the

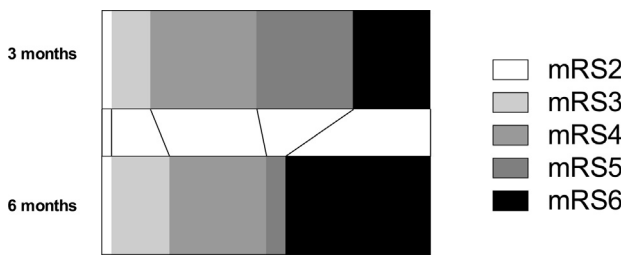

Figure 2. Outcome measured as modified Rankin Scale scores at 3 and 6 months postoperatively. Changes at the 2 time points are indicated by connecting lines. mRS, modified Rankin Scale.

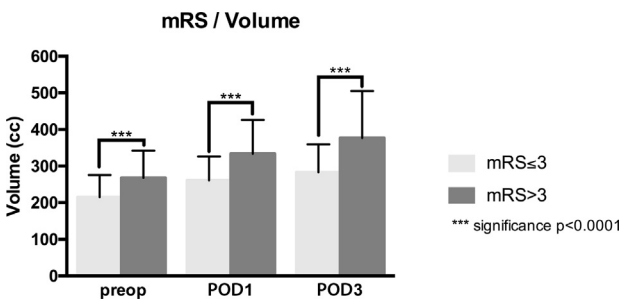

Figure 3. Correlation between outcome (modified Rankin Scale score at 6 months) and volume of ischemic brain tissue (at 3 time points: preoperatively, postoperative day 1, and postoperative day 3) (mean ± SD; ***significant with $P < 0.0001$). mRS, modified Rankin Scale; preop, preoperatively; POD, postoperative day.

development of malignant MCA infarction, although this study population comprised an elderly cohort[12] and excluded patients who had DHC. Additionally, analyzing an elderly population, with the exclusion of DHC, resulted in a higher rate of medical complications.

There were no postoperative intracerebral hemorrhages on POD 1 or POD 3 in our cohort, so any influences of hemorrhage following surgery or intravenous thrombolysis on outcomes could be ruled out. In our study, we included only patients with surgically treated stroke, with little emphasis on the presurgical medical treatment. None of the patients in our cohort was treated by mechanical thrombectomy, as it did not become an evidence-based therapy until late 2015. Furthermore, recent studies have demonstrated a significant reduction in the numbers of DHCs performed[13,14] as a result of reductions in ischemic territories secondary to recanalization.

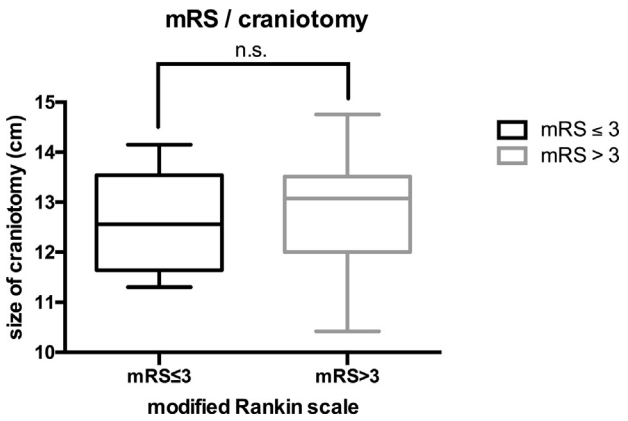

Figure 4. Relationship between the size of craniotomy and outcome (modified Rankin Scale score at 6 months). Evidence for favorable outcomes (modified Rankin Scale score ≤3) with no significant differences in terms of size of craniectomy (mean ± SD). mRS, modified Rankin Scale; n.s., not significant.

Figure 5. Illustrative computed tomography scan showing right-sided middle cerebral artery stroke. Preoperative volume of the depicted stroke was 330 cm3.

Our study has several strengths and some limitations. We report a well-characterized cohort in the absence of intracerebral hemorrhage. Furthermore, the bias that could occur based on excluding cases of endovascular thrombectomy, which would leave the more severe cases for surgical decompression, has been eliminated. All patients had a follow-up examination by an independent neurologist. The low number of study patients and the retrospective analysis study design represent shortcomings of the universal validity of the predictive value, which will need to be validated prospectively in the future.

CONCLUSIONS

The volume of ischemic brain tissue correlates with poor outcomes in surgically treated MCA infarctions. A total ischemic brain tissue volume >300 cm^3 observed on CT is a significant indicator of an unfavorable outcome in terms of an mRS score >3, with a sensitivity of 100%. DHC should be reserved for patients in whom physicians prognosticate a good outcome, which was observed only in our patients with a total preoperative ischemic tissue volume of <300 cm^3.

REFERENCES

1. Mendis S, Puska P, Norrving B. *Global Atlas on Cardiovascular Disease Prevention and Control*. Geneva: World Health Organization; 2011.

2. Goyal M, Menon BK, van Zwam WH, et al. Endovascular thrombectomy after large-vessel ischaemic stroke: a meta-analysis of individual patient data from five randomised trials. *Lancet*. 2016;387:1723-1731.

3. Juttler E, Schwab S, Schmiedek P, et al. Decompressive Surgery for the Treatment of Malignant Infarction of the Middle Cerebral Artery (DESTINY): a randomized, controlled trial. *Stroke*. 2007; 38:2518-2525.

4. Vahedi K, Vicaut E, Mateo J, et al. Sequential-design, multicenter, randomized, controlled trial of early decompressive craniectomy in malignant middle cerebral artery infarction (DECIMAL Trial). *Stroke*. 2007;38:2506-2517.

5. Hofmeijer J, Kappelle LJ, Algra A, et al. Surgical decompression for space-occupying cerebral infarction (the Hemicraniectomy After Middle Cerebral Artery infarction with Life-threatening Edema Trial [HAMLET]): a multicentre, open, randomised trial. *Lancet Neurol*. 2009;8:326-333.

6. Vahedi K, Hofmeijer J, Juettler E, et al. Early decompressive surgery in malignant infarction of the middle cerebral artery: a pooled analysis of three randomised controlled trials. *Lancet Neurol*. 2007;6:215-222.

7. Weil AG, Rahme R, Moumdjian R, Bouthillier A, Bojanowski MW. Quality of life following hemicraniectomy for malignant MCA territory infarction. *Can J Neurol Sci*. 2011;38:434-438.

8. Lin K, Lee SA, Zink WE. What ASPECTS value best predicts the 100-cm3 threshold on diffusion weighted imaging? Study of 150 patients with middle cerebral artery stroke. *J Neuroimaging*. 2011; 21:229-231.

9. Willeit J, Geley T, Schöch J, et al. Thrombolysis and clinical outcome in patients with stroke after implementation of the Tyrol Stroke Pathway: a retrospective observational study. *Lancet Neurol*. 2015;14:48-56.

10. Neugebauer H, Fiss I, Pinczolits A, et al. Large size hemicraniectomy reduces early herniation in malignant middle cerebral artery infarction. *Cerebrovasc Dis*. 2016;41:283-290.

11. Goto Y, Kumura E, Watabe T, et al. Prediction of malignant middle cerebral artery infarction in elderly patients. *J Stroke Cerebrovasc Dis*. 2016;25: 1389-1395.

12. Shi J, Cao Y, You S, et al. Young stroke patients treated with intravenous thrombolysis have a more favorable outcome and mortality compared with older patients. *Curr Neurovasc Res*. 2017;14:141-148.

13. Sporns PB, Minnerup J, Warneke N, et al. Impact of the implementation of thrombectomy with stent retrievers on the frequency of hemicraniectomy in patients with acute ischemic stroke. *Clin Neuroradiol*. 2015;27:193-197.

14. Kondziella D, Cortsen M, Eskesen V, et al. Update on acute endovascular and surgical stroke treatment. *Acta Neurol Scand*. 2013;127:1-9.

Conflict of interest statement: The authors declare that the article content was composed in the absence of any commercial or financial relationships that could be construed as a potential conflict of interest.

Received 8 October 2018; accepted 21 November 2018

Citation: World Neurosurg. (2019) 123:e515-e519. https://doi.org/10.1016/j.wneu.2018.11.197

Journal homepage: ***www.journals.elsevier.com/world-neurosurgery***

Available online: ***www.sciencedirect.com***