Journal of Oral Rehabilitation 2000 **27**; 671–681

Bilateral investigation of the temporomandibular joint. An autopsy study of edentulous individuals

I. GRUNERT*, G. J. GRUBWIESER* & H. ULMER† *Department of Restorative Dentistry and †Department of Biostatistics, University of Innsbruck, Austria

SUMMARY **Investigations concerning normal and pathological anatomy of the temporomandibular joint (TMJ) have shown that pathological reactions such as deviations of the shape of the condyle, disc thinnings, disc perforations and osteoarthrotic changes are fairly common, particularly in the elderly population. Autopsy studies of the TMJ describe pathological findings respective to their location in different age groups, but most authors describe their findings for removed joints of one side only. The specific aim of this study was therefore to investigate the intra-individual relationships between the degenerative changes and deviations concerning the articular surfaces of the TMJs and the topographical distributions of these findings. In this investigation both joints of 22 edentulous individuals between 58 and 95 years of age were studied. Correlations were found between the right and left joints with respect to the anatomical location of the pathological findings.**

Introduction

In earlier articles the temporomandibular joints have been investigated by different points of view.

Epidemiological studies of Helkimo (1974a,b) have shown that disorders of the temporomandibular joint (TMJ) were a frequent finding in the population and all age groups can possibly be involved. A longitudinal study over 9 years (Könönen, Waltimo & Nyström, 1996) demonstrated that clinical signs like TMJ-clicking increase significantly with age.

Clinical studies (Bell, 1969, 1984; Farrar & McCarty, 1979; Dolwick, Katzberg & Helms, 1983; Gelb, 1983, 1985; McHorris, 1984; Budtz-Jörgensen *et al.*, 1985; Sakurai *et al.*, 1988) verified a great variation in the appearance of complaints of the patients suffering TMJ-disorders. The number of complaints was individually different: patients with functional disorders in general showed a higher frequency of complaints; nevertheless patients showing evidence of structural changes seemed to have less complaints concerning clinical signs such as pain (Fallschüssel, 1986), the disease seemed to burn out (De Leeuw *et al.*, 1992).

Conventional radiography and tomography are aids to detect macroscopic changes of the TMJs (Rohlin, Akerman & Kopp, 1986; Peltola, 1995; Wolf, Könönen & Mäkilä, 1995). Anatomical studies investigate macroscopic and microscopic changes of the TMJ (Blackwood, 1966, 1969; Öberg *et al.*, 1971; Carlsson & Öberg, 1974; Hansson & Öberg, 1977; Pareira, 1995) in different age groups and with different dentitions. In these studies the joints were removed and examined while always investigating one side only. Pareira (1995) found that the prevalence of degenerative changes in the articular surfaces, disc perforations, disc displacements and disc deformations increased with age. Only a few anatomical studies (Ewers & Riede, 1980; Akerman, Rohlin & Kopp, 1984) have investigated the correlation between pathological findings in both sides of one individual.

Additional reasons leading to confusion and/or disagreement in the literature are as follows: (a) the TMJ as a bilateral joint with its complex anatomy; (b) the great individual variation concerning shape and size of the joint components; (c) the individually different volume and insertion of the upper head of the lateral

pterygoid muscle; (d) the connection to occlusion lead to the extraordinary position of the TMJ in the human body; and last but not least (e) the possible effect of psychological factors.

However, in accordance with biological principles which express the relationship between form and function, it seems to be most important to explain the inter-individual variation of different condyle shapes (Grunert, 1995). Hiltebrandt (1938) was the one of the first who recognized the relationship of form and function for the TMJ.

From a functional point of view, although we refer to the TMJ, it must be remembered that the mandible is the one bone in the body which is hinged on both ends and one joint cannot be moved independently from the other. Thus, if something alters function on one side, it will simultaneously alter function on the opposite side (Laskin, 1980).

The specific aim of this study is therefore to investigate the intra-individual relationships between the degenerative changes and deviations in the configuration of the articular surfaces of the TMJs and their topographical distributions.

Materials and methods

The right and left TMJs were removed from 22 edentulous individuals, 14 women (mean age $85 \pm 8{\cdot}8$ years) and eight men (mean age $74 \pm 9{\cdot}25$ years), who before death had donated their bodies to research. Information about the dental history up to their edentulism and TMJ problems before death was not available. The cadavers were fixed in formalin–carbol solution.

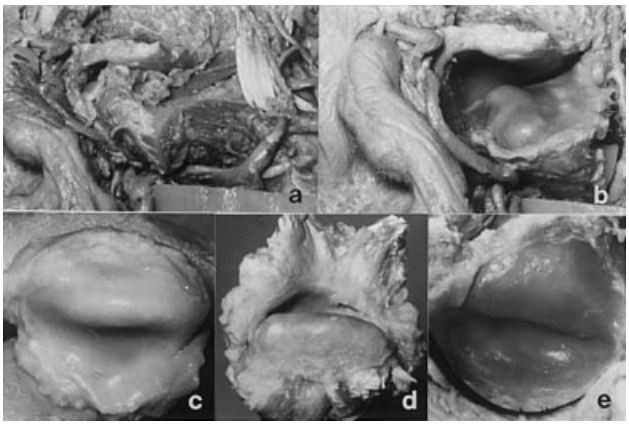

Fig. 1. Procedure of dissection. (a) Opening of the upper compartment of the joint from laterally; (b) presentation of the disc–condyle assembly; (c) removing of the disc–condyle assembly; (d) opening of the lower compartment; (e) the temporal component.

Dissection (Fig. 1)

In all cases the upper compartment of the TMJ was opened laterally (a) by a circumferential incision of the capsule; then the disc–condyle assembly was prepared (b) and removed after dissecting the condylar neck of the mandible (c); the lower compartment was opened by separating the lateral, anterior and medial attachments of the disc, the posterior attachment remained intact (d); the temporal component was photographed from below (e).

All condyles have been photographed from the anterior, lateral, medial and posterior views.

Macroscopic analysis

The shape of the condyles was divided into groups according to the frontal view described by Mongini (1972) in rounded, V-formed, lateral flattened, medial flattened, cranial flattened and irregular formed condyles. The articular surfaces of the condyles were examined for deviations in form and degenerative changes by the naked eye examination according to Moffett *et al.* (1964): progressive or regressive remodelling of the condyle, local and severe osteoarthrosis. Findings related to the disc were divided into thinnings, small and large perforations and destroyed discs. Findings in the temporal component were classified as flattening, small and severe osteoarthrotic lesions.

The location of the pathological reactions was classified by dividing every joint component into nine sections (in the medio-lateral view: medial, central and lateral parts and in the antero-posterior view: anterior, superior and posterior parts).

The data of the measurements of the joint components, the distribution of condyle form, the frequency and location of condyle remodelling and osteoarthrotic changes have already been published (Grunert, 1995, 1996).

Pathological conditions were very common in the joints of elderly, edentulous individuals. Remodellings of the condyle were found in 65% and osteoarthrotic

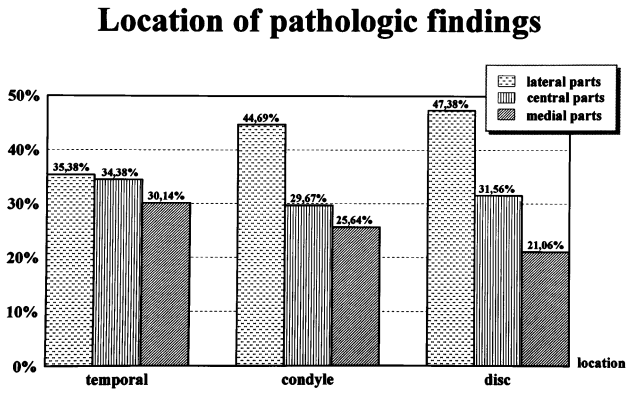

Fig. 2. Decreasing frequency of the pathological findings from lateral to the medial parts of the joint.

changes in 10%. The location of the pathological findings differed from case to case and every part of the joint could be involved. When the joints were classified in lateral, central and medial parts, changes were mostly found in the lateral third of the joint as described by Öberg *et al.* (1971). However there were also changes in the central and medial parts with decreasing frequency (Fig. 2).

Figure 3 shows the great inter-individual variation of condylar shape, the different forms and degrees of condyle remodelling and osteoarthrotic changes and the different location of the pathological findings.

Statistical methods

Spearman rank correlation coefficients were computed to evaluate pairwise associations between the variables within the temporal components, the condyles and the discs (a value of 0 indicates no relationship, a value of $+1$ a perfect positive relationship). Significance tests for independence between rank orders are performed with the Wilcoxon matched pairs signed-rank test ($P < 0{\cdot}01$).

Results of significance tests are only used in an exploratory way. Significant correlations do not allow to determine any cause-and-effect conclusion.

Intra-individual correlation. Not only statistical analysis of all data was performed, but also the relationship of the findings on both sides of every individual. The location and the degree of pathological conditions were classified into three groups:

1. Regular findings on both sides.
2. Symmetrical pathological reactions: same condylar shape, similar location and degree of pathological findings.
3. Asymmetrical reactions: different condylar shape, different location and degree of pathological findings.
   (a) One side with regular and the other with pathological findings.
   (b) Both sides with pathological findings in different locations/different degrees.

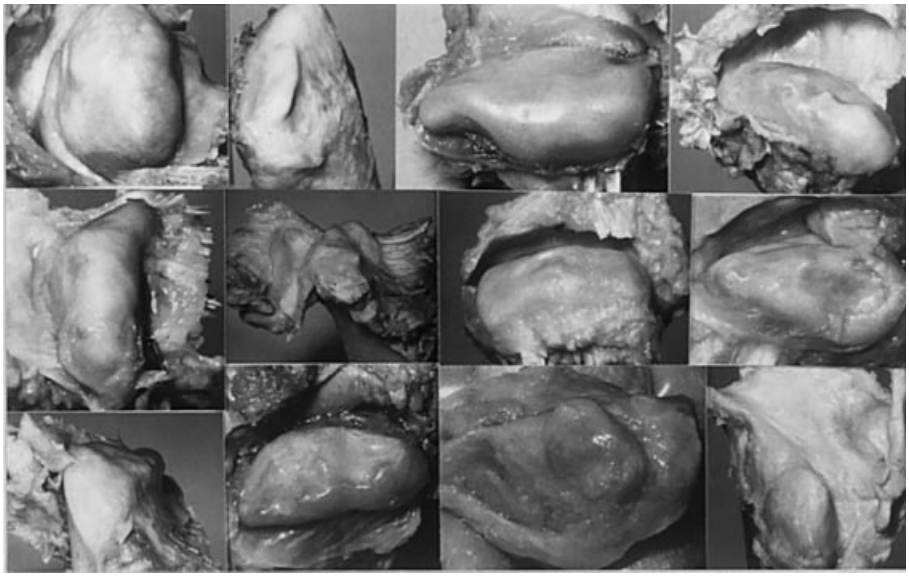

Fig. 3. Great inter-individual variation of condyle form, appearance and location of the remodelling.

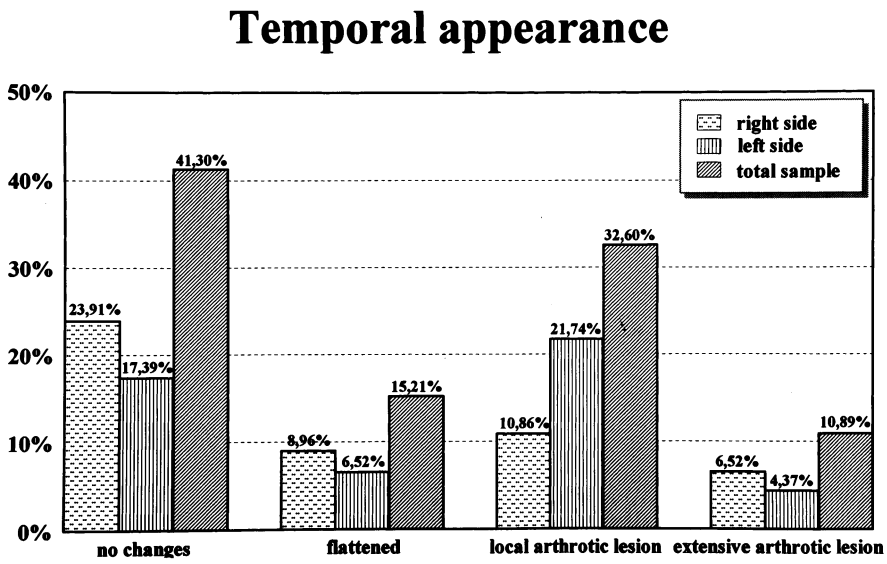

Fig. 4. Correlation of the right and left TMJ: temporal appearance.

Results

Correlation between the right and left TMJ

Temporal component (Fig. 4 and Table 1). In this study normal temporal appearance was found in 41%. In 33% local and in 11% extensive osteoarthrotic lesions could be diagnosed in the joints of the edentulous individuals. A flattening of the whole temporal component of the joint was found in 15%.

Statistical analysis of the ratings for the temporal joint components revealed a highly significant correspondence between right and left joint in all cases.

The frequency of the findings in the right and left TMJ can be seen in Fig. 4. Table 1 shows Spearman's correlation coefficients (correlation between groups of ordinal data) and belonging significances of the right and left temporal components.

Condyle appearance (Fig. 5 and Table 2). Progressive remodelling of the condyle became the most common finding and could be seen in 46% of the joints, regressive remodelling, which according to Blackwood (1966) is found particularly in edentulous subjects in older age groups, was seen in 19·55% and severe osteoarthrotic changes in 11%. Both progressive and regressive remodelling were found more often in the right condyle, compared to the left. The frequency of the findings in the right and left TMJ can be seen in Fig. 5. Table 2 shows the statistical work-out of the ratings concerning the right and left condyles. The correlation between the indices of the right and left side is less significant compared to the temporal components, nevertheless there is an accentuated correspondence between the right and left condyle particularly in the medial part.

Disc condition (Fig. 6 and Table 3). Pathological reactions were seen in more than 60%: in 28% local thinnings, in 11% small and in 13% extensive perforations. Both small and large perforations were more often seen on the right than on the left side. Macroscopic examination revealed that local thinnings and perforations of

Table 1. Spearmann's correlation coefficients and significances for the right and left temporal components

	Pathological findings			
Location	Right	Left	Correlation	Significance
Fossa lateral	3	3	0·64	$P<0·01$
Fossa central	3	4	0·55	$P<0·01$
Fossa medial	3	3	0·68	$P<0·01$
Slope lateral	5	9	0·47	$P<0·05$
Slope central	6	5	0·72	$P<0·01$
Slope medial	5	5	0·59	$P<0·01$
Crest lateral	5	5	0·58	$P<0·05$
Crest central	4	5	0·67	$P<0·01$
Crest medial	4	4	0·76	$P<0·01$

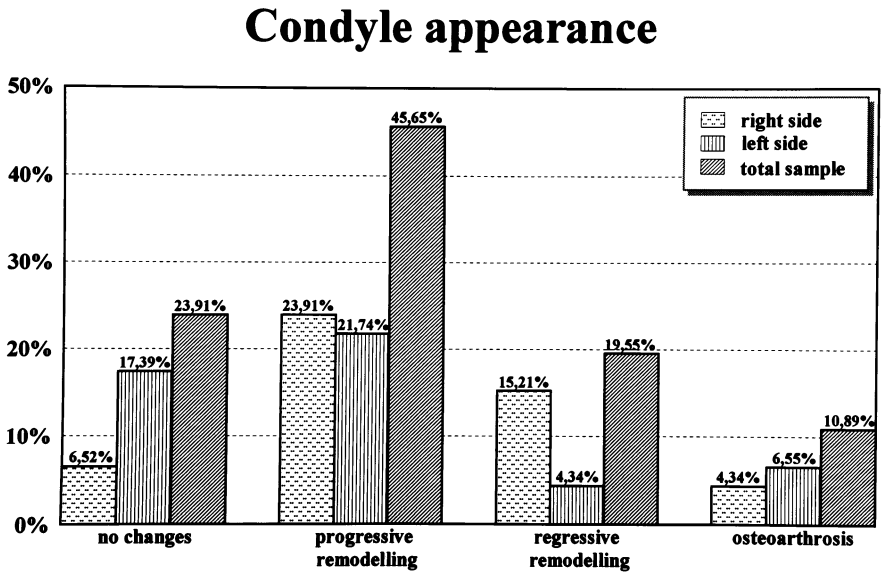

Fig. 5. Correlation of the right and left TMJ: condyle pathosis.

Table 2. Spearmann's correlation coefficients and significances for the right and left condyles

	Pathological findings			
Location	Right	Left	Correlation	Significance
Lateral posterior	6	5	0·41	n.s.
Central posterior	3	3	0·30	n.s.
Medial posterior	1	2	0·72	$P<0·01$
Lateral superior	8	5	0·38	n.s.
Central superior	6	4	0·50	n.s.
Medial superior	6	5	0·49	$P<0·05$
Lateral anterior	3	5	0·43	$P<0·05$
Central anterior	3	3	0·28	n.s.
Medial anterior	2	3	0·37	n.s.

n.s., not significant.

the disc had the same location as remodelling (progressive or regressive) of the corresponding parts of the condyle. It was also detected that destroyed discs were always accompanied by extensive remodelling of the condyles or osteoarthrotic lesions. The frequency of the findings in the right and left TMJ can be seen in Fig. 6.

Table 3 shows Spearman's correlation coefficients and belonging significances of the right and left discs. It is striking that the statistical comparison of the right versus the left side shows differences only for the lateral-posterior, medial-posterior and lateral-superior subparts of the discs whereas it is demonstrated that both, right and left discs together, are commonly affected referring to all other parts.

In Table 4 it is demonstrated that degenerative changes and deviations in tissue-configuration of the different TMJ-parts investigated in edentulous individuals show a positive correlation between the right and left joints.

Intra-individual correlation and examples:

Regular findings on both sides: five individuals

Symmetrical reactions: eight individuals. An example of a symmetrical shape on both sides were the condyles from a 91-year-old male, anterior view (Fig. 7a, b). At the changeover from the medial to the central third on the superior part, the left condyle showed a small

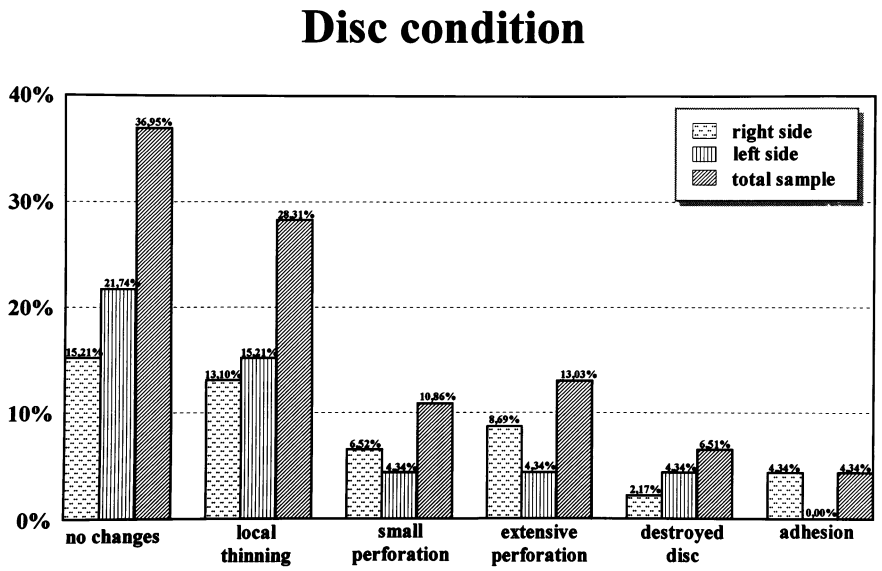

Fig. 6. Correlation of the right and left TMJ: disc condition.

Table 3. Spearmann's correlation coefficients and significances for the right and left discs

	Pathological findings			
Location	Right	Left	Correlation	Significance
Lateral posterior	5	6	0·26	n.s.
Central posterior	6	8	0·63	$P<0·01$
Medial posterior	3	3	0·19	n.s.
Lateral superior	8	6	0·10	n.s.
Central superior	2	3	0·77	$P<0·01$
Medial superior	3	4	0·46	$P<0·05$
Lateral anterior	4	4	0·44	$P<0·05$
Central anterior	2	3	0·77	$P<0·01$
Medial anterior	1	2	0·65	$P<0·01$

n.s., not significant.

osteoarthrotic lesion (arrow). This location is below an adhesion, which was found in the upper compartment of the joint (Fig. 7c, arrow).

Asymmetrical reactions: nine individuals. Two cases had one joint without pathological findings and seven cases had different conditions on both sides. In these seven cases, the most frequent locations of the pathological reactions were found in the lateral-superior parts of the joint followed by the superior and posterior central parts and the superior medial parts, whereas in the contra-lateral joints the superior medial, superior lateral, posterior and superior central parts were involved, with decreasing frequency.

The following joints of three individuals serve as examples for pathological conditions on both sides.

Joints from a 78-year-old male, the right joint in frontal and the left in superior view (Fig. 8). The left condyle showed more serious pathological findings

Table 4. Chi-square test of right and left TMJ's appearance

Source	Value	Significance
TAR–TAL	33·12	0·00013
CAR–CAL	26·03	0·00201
DCR–DCL	28·84	0·00909

TAR, temporal appearance right; TAL, temporal appearance left; CAR, condylar appearance right; CAL, condylar appearance left; DCR, disc condition right; DCL, disc condition left.



Fig. 7. Example of the symmetric shape of the condyles on both sides ((a) right condyle, (b) left condyle, (c) adhesion upper compartment). (b) The left joint shows a small osteoarthrotic lesion (arrow). (c) This osteoarthrotic lesion was below an adhesion of the upper compartment (arrow).

than the right. In lateral-superior parts of the condyle regressive remodelling and osteoarthrotic changes could be seen. There was a normal disc–condyle relationship, the disc was without perforations. Remarkable in this case was the upper head of the lateral pterygoid muscle, which impressed with increased muscle density. The contra-lateral joint showed regressive remodelling of the condyle.

The next case illustrates the joints from a 82-year-old female (Fig. 9), both joints (anterior view) presented with severe pathology. The right condyle showed regressive remodelling and flattening in all parts, the disc was anteriorly displaced with a perforation in the lateral superior part. The contra-lateral joint showed severe regressive remodelling, especially in the medial and central parts of the condyle. In this case the upper head of the lateral pterygoid muscle was also remarkably thickened.

The last case (Fig. 10) showed the severest pathology which was seen in this investigation. They were joints from a 81-year-old female. The left joint showed a large perforation of the disc and a totally destroyed condyle (superior view). The right condyle (anterior view) showed progressive remodelling of the medial third and extreme regressive remodelling in the central and lateral parts, which lead to a totally irregular shape of the condyle. The disc adapted completely to the atypical shape of the condyle.

Location of the pathological reactions of all components (Fig. 11)

When the joints were classified by dividing every joint component to nine sections (in the medio-lateral view: medial, central and lateral parts and in the antero-posterior view: anterior, superior and posterior parts) it was found that pathomorphologically relevant changes were demonstrable in every part of the joint, but the frequency decreased from lateral to the medial parts. The highest frequency of pathological reactions was seen in lateral superior parts (in all components) of the joint.

Discussion

In this study joints of edentulous individuals were investigated. The amount of pathological reactions was expected to be higher than in usual anatomical studies dealing with mixed dentitions: on the one hand because of the higher age of the edentulous cadavers and, on the other, because of the pathological reactions in the TMJ which were caused by tooth loosening and/or insufficient dentures.

In the literature there are only a few authors who have investigated TMJs on both sides (Ewers & Riede, 1980; Akerman, Rohlin & Kopp, 1984).

The results of this study are in opposition to the findings of Ewers & Riede (1980), who always de-

scribed pathological reactions symmetric in the lateral areas of the condyles. In this study symmetric findings were seen as often as asymmetric and all parts of the condyle can be involved with remodelling and osteoarthrosis.

Akerman *et al.* (1984) reported about the same number of investigated joints. They had similar results compared to this study, but their statistical analyses did not explain the connection between the pathological findings on both sides of every individual.

The most common findings in this investigation were deviations in form of the condyle, disc thinnings and perforations. They may be a result of chronic overload or a result of an aging process (Pareira, 1995) and are also seen when the disc–condyle relation is regular. Predisposing intrinsic factors for osteoarthrotic changes are age, genetics, sex, race and body overweight. Extrinsic factors are of traumatic and biomechanical nature according to the form of the joint and to chronic overload (Baici, 1998).

Chronic overload to the joints can be caused by:

1. Internal derangement of the disc–condyle assembly. Anterior disc displacement leads to disc thinnings and perforations, to condyle remodelling and osteoarthrotic lesions predominantly in the lateral-superior parts of the joint as well as in the posterior central parts in the region of the posterior disc

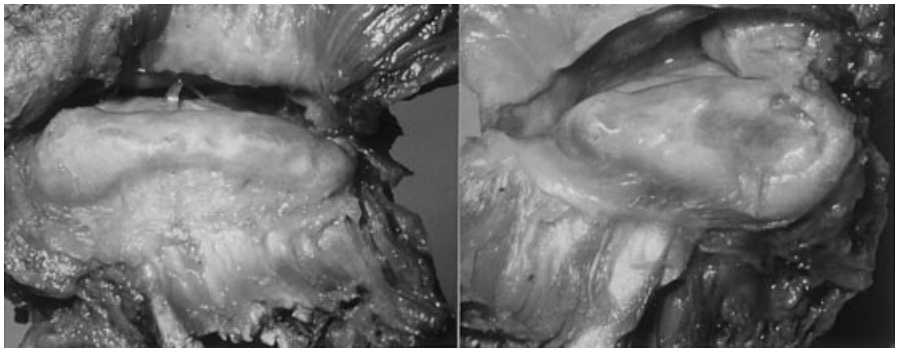

Fig. 8. Example of pathological conditions on both sides: the left joint shows extensive regressive remodelling and osteoarthrotic changes in the lateral superior parts of the condyle; the contra-lateral joint shows regressive remodelling of the condyle. Remarkable in this case is the hypertrophy of the upper head of the M. pterygoideus lateralis on both sides.

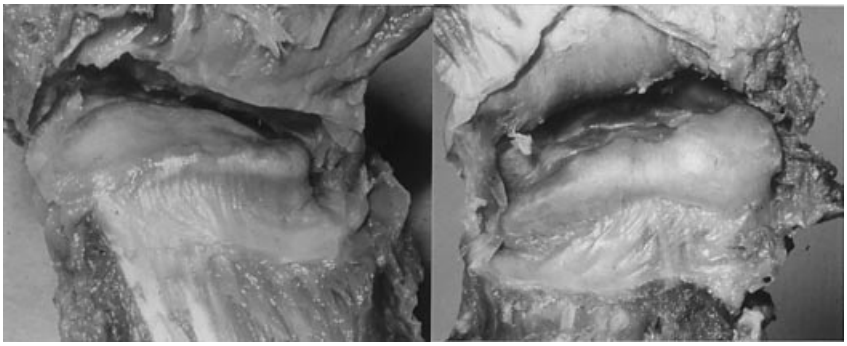

Fig. 9. Another example of pathological findings on both sides: the right condyle with severe regressive remodelling in all parts and the left with extensive regressive remodelling in the medial and central parts. Remarkable in this case is also the hypertrophy of the upper head of the M. pterygoideus lateralis on both sides.

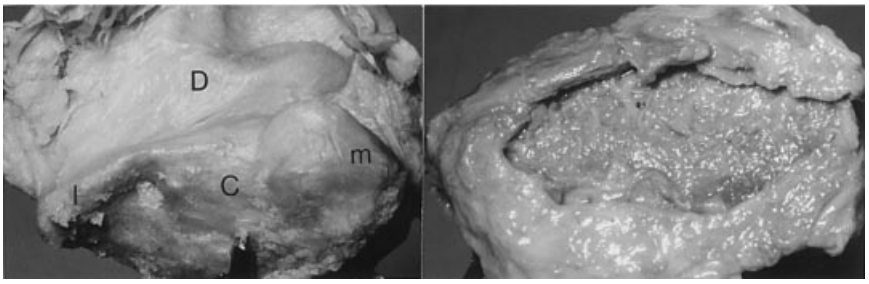

Fig. 10. Example of severe pathology on both sides: the right joint shows extensive progressive and regressive remodelling (C, condyle; D, disc; m, medial; l, lateral), the left joint shows a large disc perforation and an osteoarthrotic destroyed condyle.

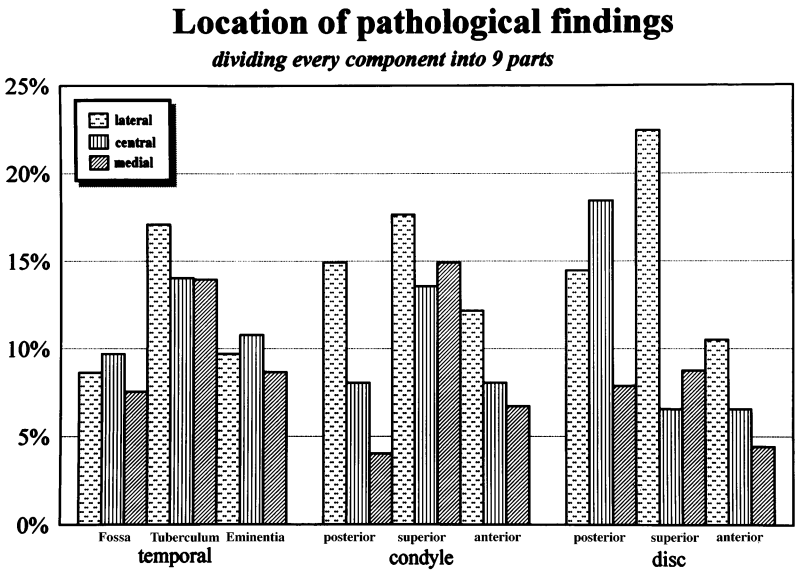

Fig. 11. Location of the pathological findings dividing every joint component to nine parts.

attachment. This pathological progression has been described by Farrar & McCarty (1979).

2. Transversal shift of the mandible (Fig. 12). Both joints are involved with different locations of the pathological reactions. The disc–condyle relationship may be regular on both sides. Through the transversal shift of the mandible there occurs an overload of the joints, which leads to contusion of the discs, disc thinnings and perforations. The condyle reacts with progressive or regressive remodelling on both sides with different locations (on one joint are the lateral parts involved and on the contra-lateral the medial and central areas). This transversal shift of the mandible has been described by Gerber (1971).
3. Bruxism with hypertrophy of the masticatory muscles may also lead to degenerative changes of the condyle through chronic overload of the joints (Clark *et al.*, 1989) (Figs 8 and 9), while the disc–condyle assembly may be discoordinated often combined with restricted condyle translation. Degenerative changes seem to increase the progressive remodelling which leads to deviations in the configuration of the joint (Palla, 1998). Remodelling of the joint may be therefore a hopeless, useless and overshooting reparative attempt of the body to prevent or repair a damage and may not be a reaction to biomechanic stress (Luder, 1993).

Conclusion

As a bilateral joint with complex anatomy and because of the connection to occlusion and to the influence of psychological factors, the TMJ has an exceptional position in the human body. However, it functions in accordance to biological principles and the relation between form and function seems to be the most important.

Contrary to Öberg *et al.* (1971) and Hansson & Öberg (1977) pathological findings can be seen in every part of the joint, also in the medial parts. In cases when pathological findings are found in both joints, the most common location in the joint with severe pathology is

Fig. 12. Transversal shift of the mandible leads to pathological reactions on both sides in different locations.

in the lateral third, whereas the contra-lateral joint reveals pathological findings in the medial and central parts. This can be explained by transversal shift of the mandible, which leads to local overload in both joints.

It is concluded that degenerative changes and deviations in form in edentulous individuals are correlated between the right and the left joints.

References

AKERMAN, S., ROHLIN, M. & KOPP, S. (1984) Bilateral degenerative changes and deviation in form of temporomandibular joints. An autopsy study of elderly individuals. *Acta Odontologica Scandinavica*, **42,** 205.

BAICI, A. (1998) Arthrose als frustrieter Reparaturvorgang. In: *Myarthropathien des Kausystems und orofaciale Schmerzen* (ed. S. Palla). Zentrum Für Zahn-, Mund- und Kieferheilkunde der Universität Zürich.

BELL, W. (1969) Clinical diagnosis of the pain–dysfunction syndrome. *Journal of American Dental Association*, **79,** 154.

BELL, W. (1984) On TMJ function and dysfunction. *Journal of Clinical Orthodontics*, **18,** 877.

BLACKWOOD, H. (1966) Adaptive changes in the mandibular joints with function. *Dental Clinics of North America*, **10,** 559.

BLACKWOOD, H. (1969) Pathology of the temporomandibular joint. *Journal of American Dental Association*, **79,** 118.

BUDTZ-JÖRGENSEN, E., LUAN, W., HOLM-PEDERSEN, P. & FEJERSKOV, O. (1985) Mandibular dysfunction related to dental, occlusal and prosthetic conditions in a selected elderly population. *Gerodontics*, **1,** 28.

CARLSSON, G. & ÖBERG, T. (1974) Remodeling of the temporomandibular joints. *Oral Science Reviews*, **6,** 53.

CLARK, G., SELIGMAN, D., SOLBERG, W. & PULLINGER, A. (1989) Guidelines for the examination and diagnosis of temporomandibular joint disorders. *Journal of Craniomandibular Disorders*, **3,** 7.

DE LEEUW, R., BOERING, G., STEGENGA, B. & DE BONT, L. (1992) Long-term clinical and radiographic follow-up of temporomandibular joint osteoarthrosis. *Journal of Oral Rehabilitation*, **19,** 169.

DOLWICK, F., KATZBERG, R. & HELMS, C. (1983) Internal derangements of the temporomandibular joint: fact or fiction? *Journal of Prosthetic Dentistry*, **49,** 415.

EWERS, R. & RIEDE, U. (1980) Funktionsanalyse des Kiefergelenkes. Eine morphometrische und biometrische Studie. *Fortschritte der Kiefer- und Gesichtschirurgie*, **25,** 11.

FALLSCHÜSSEL, G. (1986) Geistig-seelische Einflüsse bei Störung im Kausystem: Fakten-Empirie-Hypothesen. *Deutsche Zahnärztliche Zeitschrift*, **41,** 271.

FARRAR, W. & MCCARTY, W. (1979) The TMJ dilemma. *Journal of Alabama Dental Association*, **63,** 19.

GELB, H. (1983) Clinical evaluation of two hundred patients with temporomandibular joint syndrome. *Journal of Prosthetic Dentistry*, **49,** 234.

GELB, H. (1985) The optimum temporomandibular joint condyle position in clinical practice. *International Journal of Periodontics and Restorative Dentistry*, **5,** 34.

GERBER, A. (1971) Kiefergelenk und Zahnokklusion. *Deutsche Zahnärztliche Zeitschrift*, **26,** 119.

GRUNERT, I. (1995) *Die Kiefergelenke des Zahnlosen-Eine anatomische und klinische Untersuchung. Habilitationsschriften*. Quintessenz, Berlin.

GRUNERT, I. (1996) Autopsieuntersuchung der Kiefergelenke Zahnloser. *Zeitschrift für Stomatologie*, **93,** 417.

HANSSON, T. & ÖBERG, T. (1977) Arthrosis and deviation in form in the temporo-mandibular joint. A macroscopic study on a human autopsy material. *Acta Odontologica Scandinavia*, **35,** 167.

HELKIMO, M. (1974a) Studies on function and dysfunction of the masticatory system. II. Index for anamnestic and clinical dysfunction and occlusal state. *Svensk Tandlakaretdskrift*, **67,** 101.

HELKIMO, M. (1974b) Studies on function and dysfunction of the masticatory system. III. Analyses of anamnestic and clinical recordings of dysfunction with the aid of indices. *Svensk Tandlakaretdskrift*, **67,** 165.

HILTEBRANDT, C. (1938) Die Unterkiefer-Bewegungen und ihre Beziehungen zum Kiefergelenk. *Zahnärztliche Welt*, **34,** 570.

KÖNÖNEN, M., WALTIMO, A. & NYSTRÖM, M. (1996) Does clicking in adolescence lead to painful temporomandibular joint locking? *Lancet*, **347,** 1080.

LASKIN, D. (1980) Surgery of the temporomandibular joint. In: *Temporomandibular Joint Problems. Biologic Diagnosis and Treatment* (eds W. Solberg & G. Clark). Quintessence, Chicago.

LUDER, H.U. (1993) *Postnatal development, aging and degeneration of the temporomandibular joint in humans, monkeys and rats*. Craniofacial growth series, Vol. 32. Med. Habil. Zürich: Medizinische Fakultät der Universität Zürich.

MCHORRIS, W. (1984) The condyle-disc dilemma. *Journal of Gnathology*, **3,** 3.

MOFFETT, B., JOHNSON, L., MCCABE, J. & ASKEW, H. (1964) Articular remodeling in the adult human temporomandibular joint. *American Journal of Anatomy*, **115,** 119.

MONGINI, F. (1972) Remodeling of the mandibular condyle in the adult and its relationship to the condition of the dental arches. *Acta Anatomica*, **82,** 437.

ÖBERG, T., CARLSSON, G.E. & FAJERS, C.M. (1971) The temporomandibular joint. A morphologic study on a human autopsy material. *Acta Odontologica Scandinavica*, **29,** 349.

PALLA, S. (1998) Myarthropathien des Kausystems. In: *Myarthropathien des Kausystems und orofaciale Schmerzen* (ed. S. Palla). Zentrum Für Zahn-, Mund- und Kieferheilkunde der Universität Zürich.

PAREIRA, F. (1995) *Macroscopic and microscopic findings in the temporomandibular joint. A clinical and autopsy study with reference to age, sex, and signs and symptoms*. Thesis, University of Malmö.

PELTOLA, J. (1995) *Radiographic structural findings in the mandibular condyles of orthodontically treated children and young adults*. Thesis, University of Helsinki.

ROHLIN, M., AKERMAN, S. & KOPP, S. (1986) Tomography as an aid to detect macroscopic changes of the temporomandibular joint. *Acta Odontologica Scandinavica*, **44,** 131.

SAKURAI, K., SAN GIACOMO, T., ARBREE, N.S. & YURKSTAS, A. (1988) A survey of temporomandibular joint dysfunction in completely edentulous patients. *Journal of Prosthetic Dentistry*, **59,** 81.

WOLF, J., KÖNÖNEN, M. & MÄKILÄ, E. (1995) Radiographic signs in the TMJ and finger joints in elderly people. *Journal of Oral Rehabilitation*, **22,** 269.

Correspondence: Prof. Dr Ingrid Grunert, Department of Restorative Dentistry, Dental School, University of Innsbruck, Anichstraße 35, A-6020 Innsbruck, Austria. E-mail: zahnersatz.zahnerhaltung@uklibk.ac.at